
Guidelines for Managing the Orthodontic-Restorative Patient

Vincent G. Kokich and Frank M. Spear

Occasionally, patients require restorative treatment during or after orthodontic therapy. Patients with worn or abraded teeth, peg-shaped lateral incisors, fractured teeth, multiple edentulous spaces, or other restorative needs may require tooth positioning that is slightly different from a nonrestored, nonabraded, completely dentulous adolescent. Generally, orthodontists are not accustomed to dealing with patients who require restorative intervention. Should the objectives of orthodontic treatment differ for the restorative patient compared with the nonrestorative patient? How should the teeth be positioned during orthodontic therapy to facilitate specific restorations? Should teeth be restored before, during, or perhaps after orthodontics? The answers to these and other important questions are vital to the successful treatment of some orthodontic patients. This article will provide a series of eight guidelines to help the interdisciplinary team manage treatment for the orthodontic-restorative patient. (Semin Orthod 1997;3:3-20.) Copyright © 1997 by W.B. Saunders Company

The widespread use of fluoride and occlusal sealants since the 1970s, has reduced the caries rate in the United States. In the 1990s, most adolescent orthodontic patients have no restorations at the completion of orthodontic treatment. However, as we approach the 21st century, orthodontists will be treating more adult patients. Many of these adult patients have not benefited from caries prevention during childhood. As a result, the adult orthodontic population may have previous restorations, worn or abraded teeth, missing teeth, malformed teeth, and other problems that require not only orthodontics but also restorative dentistry. The orthodontic treatment for these patients must be planned in conjunction with the restorative dentist to establish proper tooth position facilitating restoration of the teeth following orthodontic therapy. The latter requires teamwork. To accomplish the optimum result for these orthodontic-

restorative patients, the team must follow certain steps or guidelines. This article will describe a series of eight guidelines to help the team integrate orthodontic and restorative therapy.

Establish Realistic Treatment Objectives

The first step in any type of dental therapy is to establish treatment objectives. It is impossible to achieve the correct end result if the appropriate goals or objectives have not been identified before treatment. In nonrestored, adolescent patients with complete dentitions, orthodontic treatment objectives tend to be idealistic. If patients have intact dentitions without restorations, it is appropriate to expect that ideal esthetic and occlusal treatment objectives should be attainable if the patient cooperates. Because of this, most orthodontists are trapped into applying these same idealistic treatment objectives to adult patients with missing teeth, abraded teeth, old restorations, or other restorative requirements. Idealistic treatment objectives may not be appropriate for the orthodontic-restorative patient. For these types of patients, it is important to establish realistic, not idealistic treatment objectives.

Realistic treatment objectives fall into three

From the Department of Orthodontics, School of Dentistry, University of Washington, Seattle, WA.

Address correspondence to Vincent G. Kokich, DDS, MSD, Department of Orthodontics, School of Dentistry, University of Washington, Seattle, WA 98195.

*Copyright © 1997 by W.B. Saunders Company
1073-8746/97/0301-0002\$5.00/0*

categories. These objectives should be economically realistic, occlusally realistic, and restoratively realistic. If an adult orthodontic patient is missing several teeth, the edentulous spaces created during orthodontic treatment will require restoration after the removal of the orthodontic appliances. Several restorative alternatives may exist for replacing the missing teeth. The cost of these restorative treatment plans may differ widely. Furthermore, each type of restoration may require slightly different tooth positioning. Therefore, it is important for the team to establish an orthodontic-restorative treatment plan that is economically realistic for each patient. If the team fails to establish economically realistic objectives, the patient might not complete the restorative treatment following orthodontic therapy.

If patients are missing many teeth, it may not be prudent to establish idealistic occlusal objectives. An ideal Angle Class I posterior occlusion is achievable in a patient with a complete, nonrestored, nonabraded dentition. However, if the patient is missing several teeth and will require extensive restorative treatment after orthodontics, it may be prudent to establish treatment objectives that are occlusally realistic for that specific patient. For example, if the patient will require extensive restorations after orthodontic treatment, the restorative dentist may suggest altering an Angle Class I occlusion to facilitate restoration of the teeth. It is critical for the orthodontist to be aware of these alterations before bracket placement to achieve an occlusally realistic relationship for the restorative patient.

Certain types of restorations require specific positioning of adjacent or opposing teeth. As a result, orthodontists must not establish idealistic treatment objectives for patients who will require extensive restoration. If teeth are worn or abraded, it may be more important to position the teeth in a restoratively realistic location to facilitate the appropriate restoration.

Create the Vision

After an orthodontist has treated several hundred adolescent patients with complete dentitions, it is easy to visualize or foresee the final orthodontic result before beginning treatment. However, some adult orthodontic patients may be missing several permanent teeth. If teeth have

been absent for several years, the remaining teeth may have drifted. These patients will require a combination of orthodontics and restorative dentistry to rehabilitate their occlusion.

In these patients, it may be difficult for the orthodontist to visualize or foresee the final result. Orthodontists may not be aware of the restorative requirements or the eventual restorative treatment plan. It is also difficult for the restorative dentist to visualize the final result. The restorative dentist may not know the orthodontic possibilities. However, it is possible to predetermine the final occlusal and restorative outcome by completing a diagnostic wax set-up for these types of patients (Fig 1). A diagnostic set up is mandatory for any patients who are missing multiple permanent teeth and who will require a combination of orthodontics and restorative dentistry. The orthodontist should not make the restorative decisions, but should consult with the restorative dentist while planning treatment for these types of patients. In that way, the orthodontist may reposition the teeth to simulate realistic orthodontic objectives that will be in harmony with the patient's restorative requirements. Then both practitioners, as well as the patient, can visualize the result. The diagnostic wax set-up is the blueprint for treatment in these types of patients.

Determine the Sequence of Treatment

Many orthodontic-restorative patients also require adjunctive periodontal therapy and orthognathic surgery. As the numbers of dentists involved in a patient's treatment increase, the complexity of the treatment also increases. In many of these situations, different specialists must interact at varying intervals during the patient's overall treatment. Therefore, the team of specialists must not only establish a realistic plan of treatment, but they should also determine the sequence of interaction between different specialists (Fig 2).

This is a critical step that requires that the team members meet to discuss the patient's treatment before the initiation of therapy. After the sequence of intervention has been determined, it should be recorded by one of the clinicians. A copy of the sequence should be given to each of the participating dentists. Then, at any time during treatment, any of the team

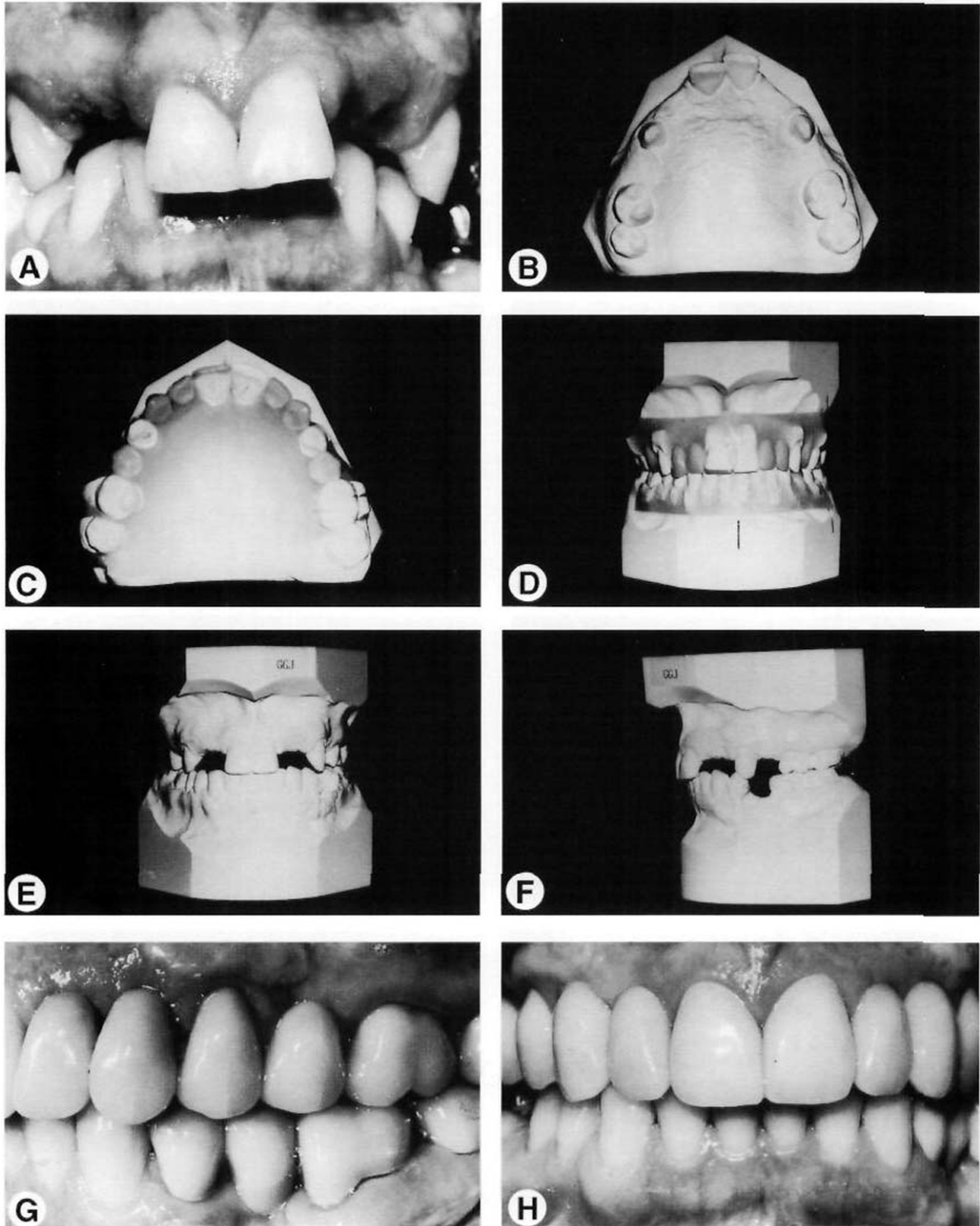


Figure 1. This patient was congenitally missing the maxillary right and left lateral incisors, first premolars and second premolars (A and B). To produce the correct tooth position for the restorative dentist, it was necessary to construct a diagnostic wax-up to simulate the amount of pontic space for the missing teeth (C and D). The diagnostic wax-up provided the blueprint for proper tooth position, so the restorative dentist had the appropriate amount of space to create ideal restorations for this patient (E-H).

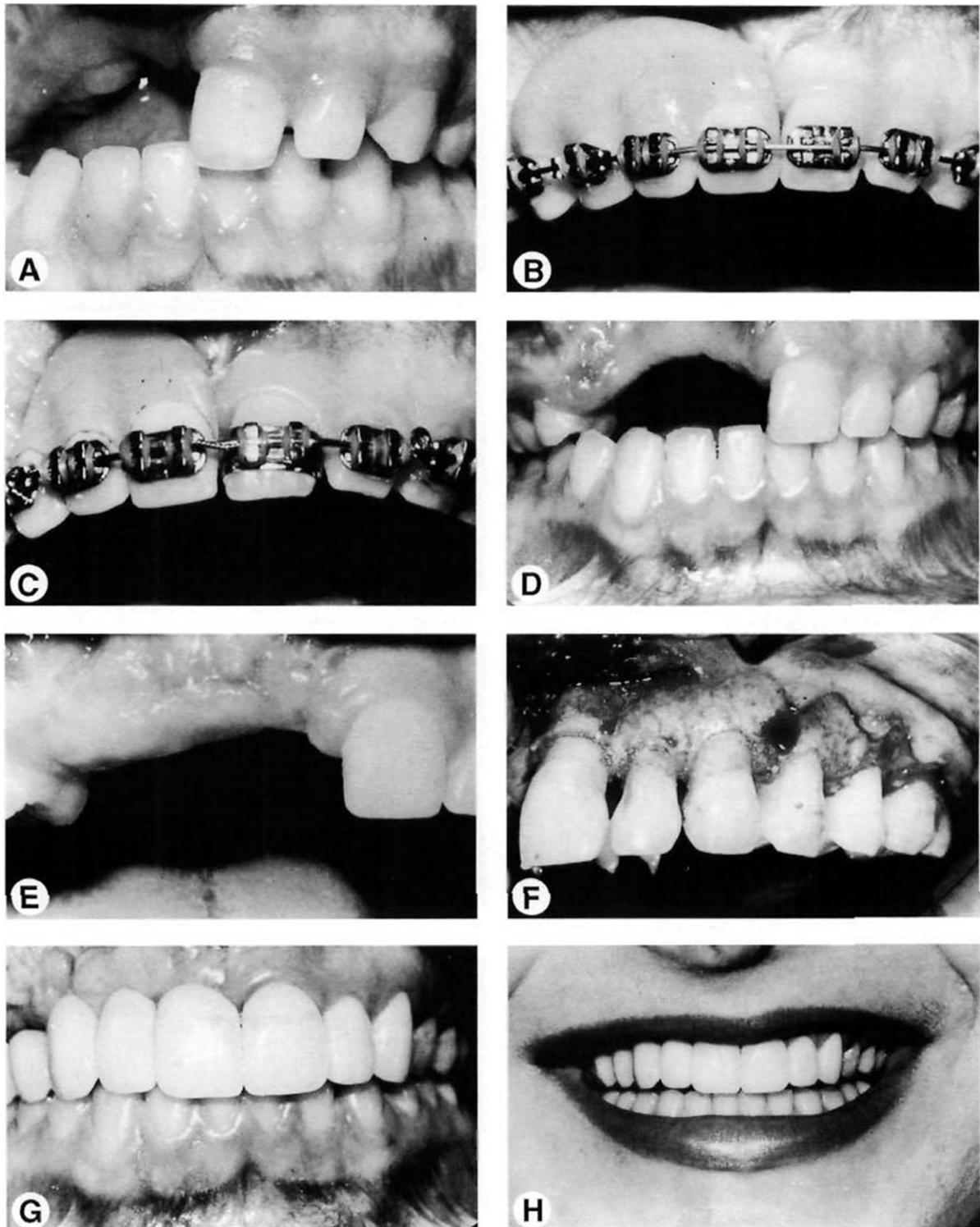


Figure 2. This patient had an accident that avulsed the maxillary right central incisor, lateral incisor, canine, and first premolar, and required an extremely complicated treatment plan with intervention of several specialists. To determine the proper sequence of orthodontics, periodontics, ridge grafting, jaw surgery, and restorations, the team met before orthodontic therapy. The treatment sequence was established and followed throughout in order to achieve an ideal functional and esthetic result. Establishing the sequence of treatment is important for patients receiving interdisciplinary treatment from a variety of specialists.

members can review the sequence, determine their point of interaction, and feel secure that the plan is proceeding properly. The importance of this step cannot be overemphasized. The success in treating a patient with complex restorative, periodontal, orthognathic, and orthodontic problems is dependent on not only the correct plan of treatment, but also the correct sequence of interaction among different practitioners during that patient's treatment.

Build-up Small, Malformed Teeth

Some orthodontic-restorative patients have small, malformed teeth that will eventually require restoration after the completion of orthodontic treatment. In most of these situations, the orthodontist must create additional space to restore these teeth. Ideally, these restorations should be placed before the initiation of orthodontic therapy. However, in many situations, there is not enough space to restore the tooth before orthodontic treatment. The team must decide how much space to create for these restorations and the timing of restoring these small or malformed teeth. Two situations are common: retained primary teeth and peg-shaped lateral incisors.

Retained Primary Teeth

Occasionally, patients may be congenitally missing permanent teeth. In some of these situations, the primary teeth are retained indefinitely. In these orthodontic-restorative patients, the primary teeth may be replaced eventually with permanent restorations. In some of these patients, implants could be used to replace the missing teeth. If implants are an option, it is important to retain the primary tooth as long as possible to maintain the width of the alveolar ridge.^{1,2} However, primary teeth are often smaller than permanent teeth. To establish the correct occlusion, space should be created mesial and distal to most primary teeth so that they can be restored temporarily during orthodontic treatment (Fig 3).

Commonly retained primary teeth are mandibular central incisors, maxillary lateral incisors and maxillary canines. In all three situations, the permanent replacement for these teeth will be wider mesiodistally than the primary tooth. It is preferable to build-up these teeth with a composite restoration before orthodontic therapy. How-

ever, in most instances, there is insufficient space to build-up the teeth. Therefore, during orthodontics, space must be created to restore these teeth to their appropriate width. It is often necessary to create a diagnostic wax-up to simulate the correct width of the composite restoration. Some of these primary teeth can be retained indefinitely if their roots do not resorb. By creating the correct width, both esthetics and occlusion are enhanced.

Peg-Shaped Lateral Incisors

A common orthodontic-restorative problem is peg-shaped, or malformed maxillary lateral incisors. In some patients, the best choice for treating a peg-shaped lateral incisor is to restore the malformed tooth to its correct dimension.^{3,4} If sufficient space exists, a composite restoration may be placed before orthodontic treatment (Fig 4). However, in most situations, there is insufficient space to restore the malformed lateral incisors. Therefore, orthodontics is often necessary to create space to build-up peg-shaped lateral incisors.

The orthodontic mechanics to open space mesial and distal to the lateral incisor are relatively simple. Compressed coil springs are placed between the central incisor, lateral incisor and canine, to push the central and canine away from the lateral incisor (Fig 5). Space will be generated in a few weeks. As space is created, four questions must be answered. First, how much space is required to restore the lateral incisor? This may seem obvious. If the patient has an existing lateral incisor of normal width on the opposite side, it seems logical to create the same amount of space. However, it is advantageous to create extra space. This will allow the restorative dentist to contour and polish the interproximal surfaces of the temporary composite restoration so it matches the width of the opposite lateral. If the patient is congenitally missing the opposite lateral incisor, a diagnostic wax-up should be constructed (Fig 4). This will determine the correct size for the restoration of the peg-shaped lateral incisor.

When creating space orthodontically, a second question arises. Where should the maxillary lateral incisor be positioned mesiodistally relative to the central incisor and canine? If the lateral incisor is positioned too close to the canine, the mesial surface of the lateral must be

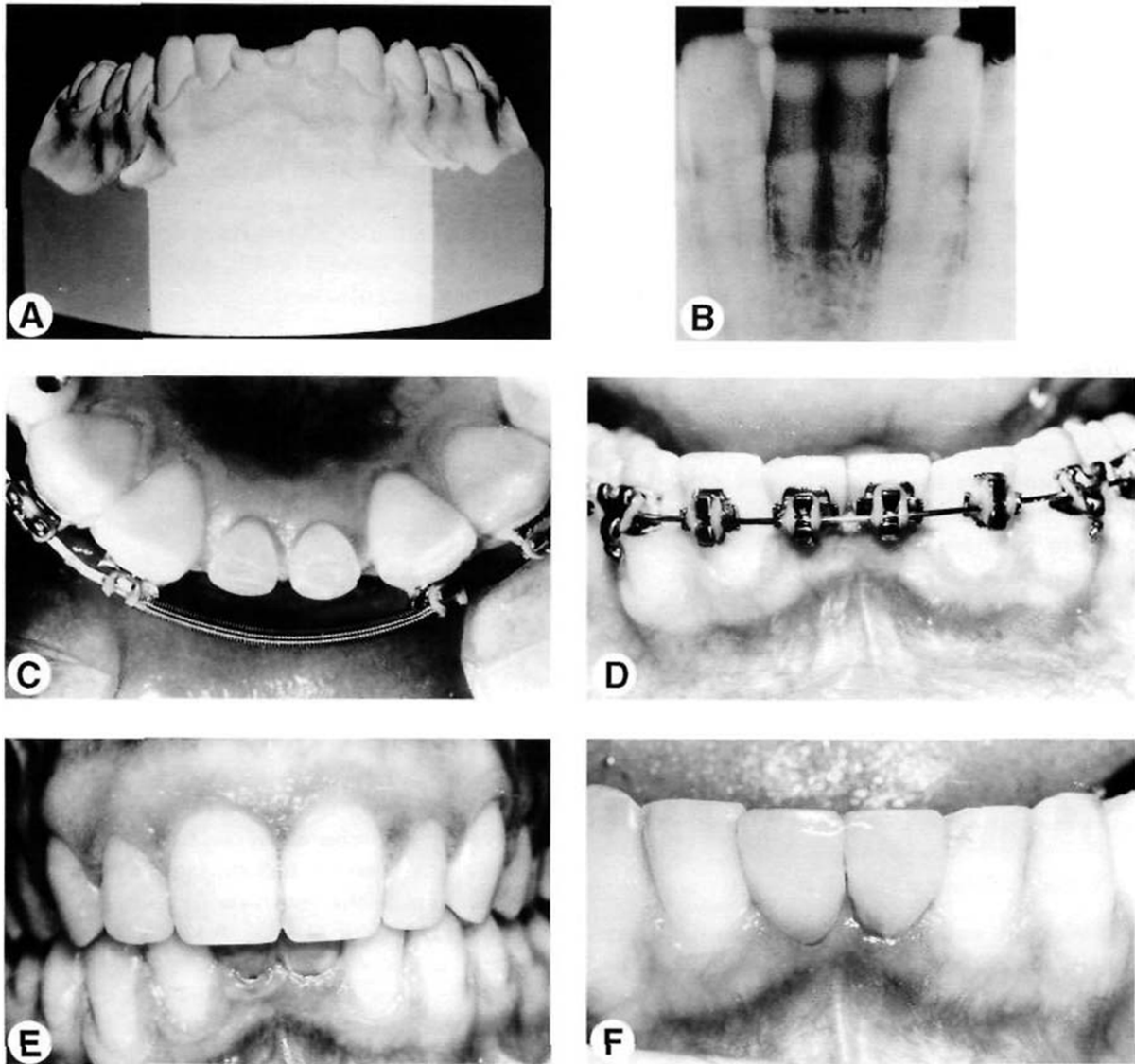


Figure 3. This patient is congenitally missing both mandibular central incisors (A and B). Implants were planned for the mandibular anterior region, so the primary central incisors were maintained to retain the alveolar bone. Space was opened between the lateral incisors (C) and the primary central incisors were restored provisionally with composite to maintain the space (D-F).

overcontoured to achieve the correct width of the lateral incisor restoration. The result of this could be unesthetic. The emergence profile or contour of the mesial surfaces of lateral and central incisors is relatively flat. The distal surfaces of central and lateral incisors are more contoured or convex. Therefore, the peg-shaped lateral incisor should be positioned nearer the central incisor than the canine during orthodontic treatment (Fig 5).

Where should the lateral incisor be positioned buccolingually: toward the labial, in the center of the ridge, or toward the lingual? The

answer to this question depends on the type of permanent restoration that will eventually be constructed for the tooth. In most cases, during orthodontic treatment, a temporary composite build-up is placed on a peg-shaped lateral incisor. However, eventually, this tooth may be restored with either a porcelain laminate or a porcelain crown. If the eventual restoration will be a porcelain crown, the lateral incisor should be positioned in the center of the ridge buccolingually, leaving 0.50 to 0.75 mm of overjet. This will avoid additional tooth preparation on the lingual of the lateral and permit space for gold

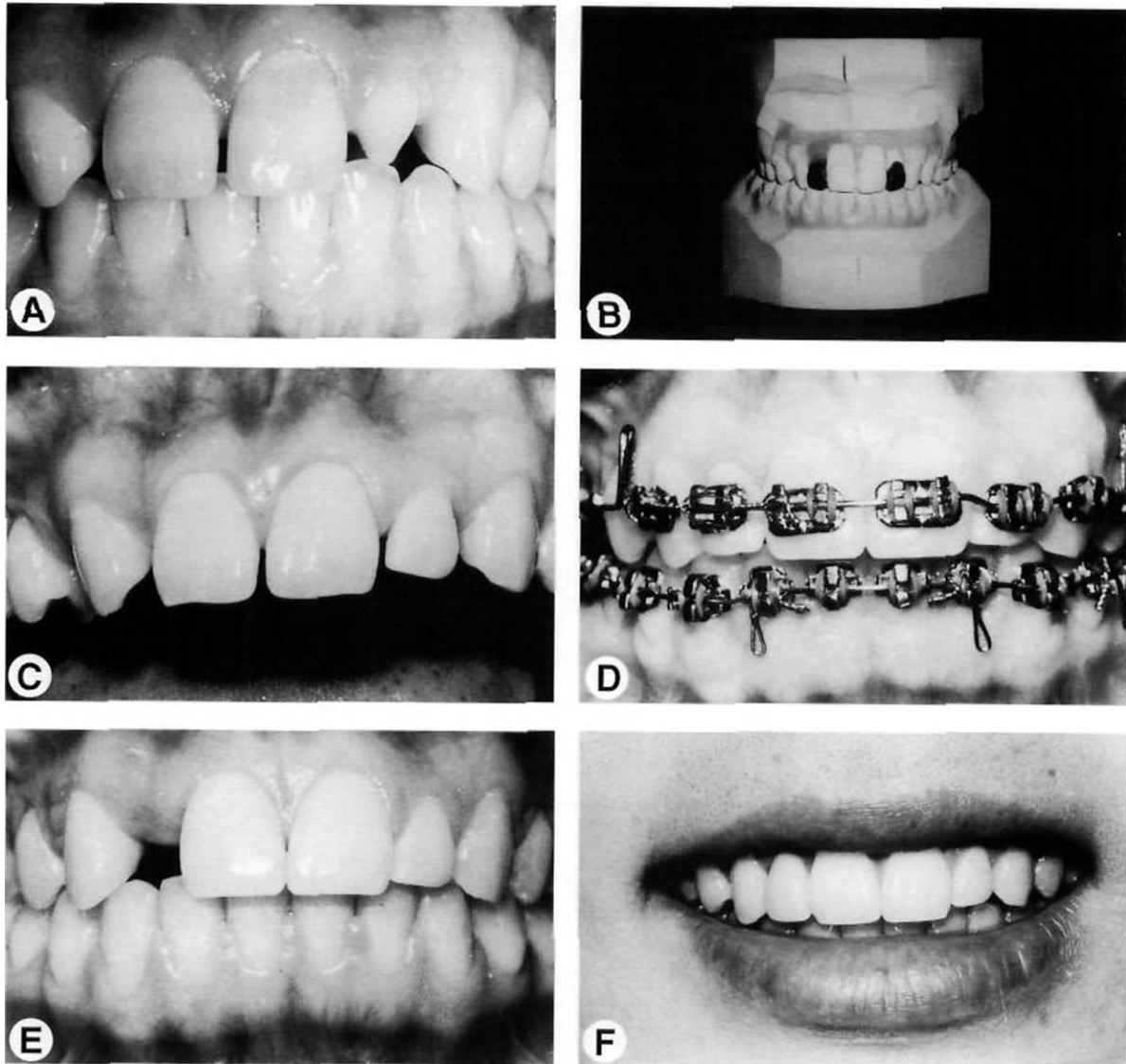


Figure 4. This patient was congenitally missing the maxillary right lateral incisor (A). The left lateral incisor was peg-shaped and required temporary restoration to create the proper width. A diagnostic set-up was constructed (B) to provide a guide for restoring the left lateral incisor (C). By building up the lateral incisor before orthodontics, the orthodontic and restorative treatments were simplified (D-F).

and/or porcelain in the final restoration. However, if the final restoration will be a porcelain veneer, then the peg-shaped lateral should be positioned lingually to contact the mandibular incisors in centric occlusion. This will allow sufficient space on the labial to construct both the temporary composite build-up and the eventual porcelain laminate.

Finally, where should the lateral incisor be positioned incisogingivally? This relationship is determined by the position of the gingival margins (Fig 5). Most peg-shaped lateral incisors are not only narrower mesiodistally and buccolin-

gually, they are also shorter than normal lateral incisors incisogingivally. If the incisal edge is aligned with the opposite lateral incisor, the crown may be too short. Therefore, the gingival margins of the peg-shaped lateral should be aligned with the contralateral lateral incisor. The restorative dentist will restore proper length, width, and thickness of the tooth when the temporary composite build-up and final restoration are constructed.

Another consideration in the interdisciplinary management of peg-shaped lateral incisors is when to restore the malformed tooth. In some

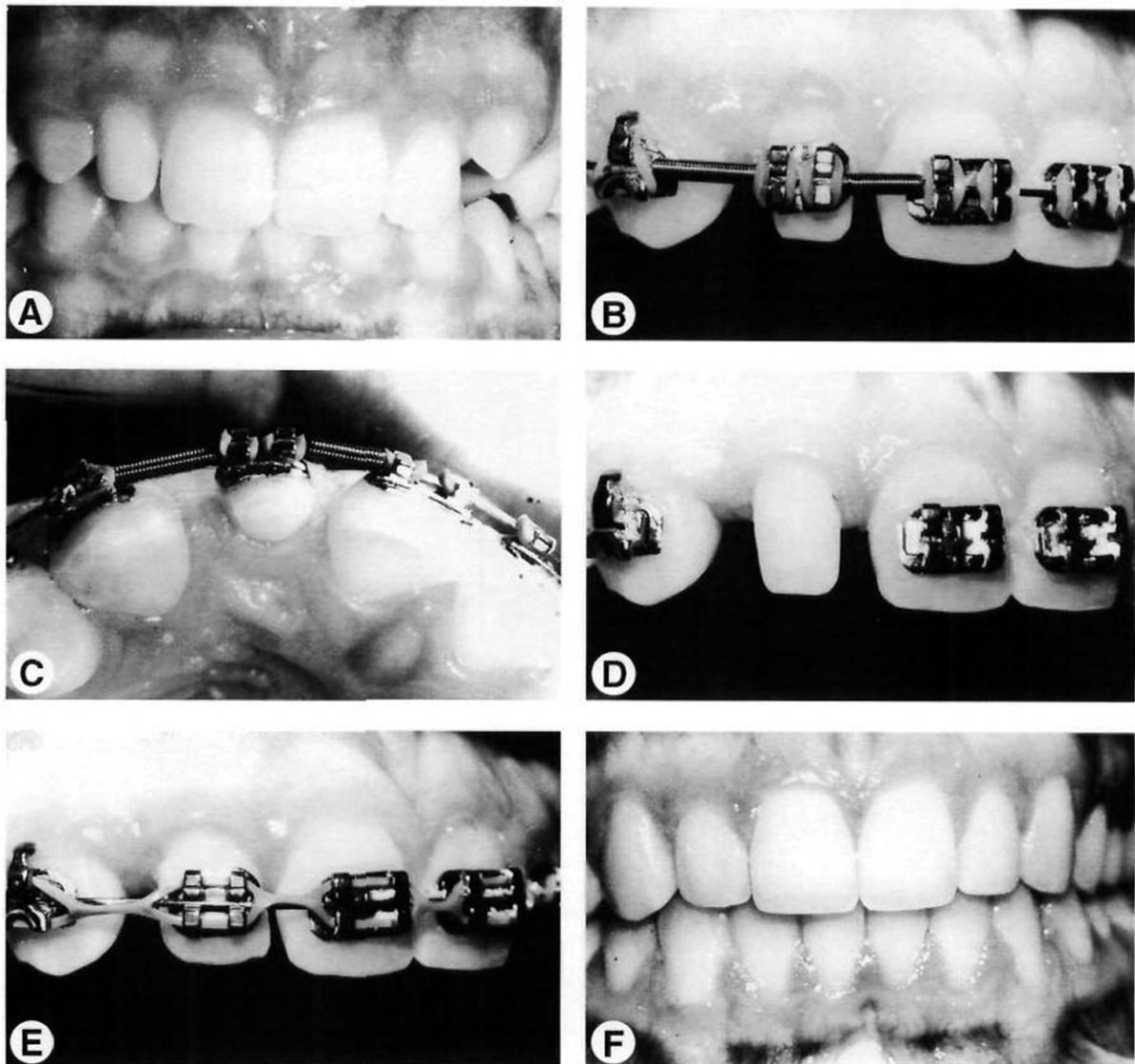


Figure 5. This patient had a peg-shaped maxillary right lateral incisor (A). Coil springs were used to open space between the canine, lateral incisor and central incisor (B and C). By creating the appropriate space and positioning the lateral incisor correctly, a composite restoration could be placed to enhance the occlusion and the esthetic appearance of the teeth (D-F).

situations, a peg-shaped lateral incisor may be restored before orthodontic treatment. However, this may only be accomplished if sufficient space exists between the lateral incisor and adjacent canine and central (Fig 4), but this rarely occurs. Therefore, in most situations, the orthodontist and restorative dentist must work closely to manage the restoration of the peg-shaped lateral during orthodontic treatment. Because the orthodontist will be creating extra space, it is advantageous to place the restoration during orthodontic treatment. The patient should visit the orthodontist's office first, to

remove the bracket and residual cement. The restorative dentist can then bond a composite restoration to the lateral incisor to create normal crown shape and size (Fig 5). A bracket is replaced on the tooth to permit completion of the orthodontic treatment and then the orthodontist may close any extra space and create more ideal tooth position.

When making the decision to restore a peg-shaped lateral incisor, several concerns must be addressed. First, the cervical portion of a malformed lateral incisor is usually narrower mesio-distally than a normal lateral incisor. The restora-

tion will therefore need to be overcontoured. The clinician must be careful to blend the restorative material into the tooth surface to avoid a ledge. A second concern is the life of the restoration. If a peg-shaped lateral incisor is restored in a young adult, this tooth may need to be restored several more times over the patient's lifetime. This could be less ideal than extracting the peg-shaped lateral incisor. However, if the tooth can be restored with a porcelain laminate rather than a crown, the negative impact of multiple restorations will be reduced. A third

concern is esthetics. If a restoration is placed on the peg-shaped lateral incisor, it is important to position the tooth ideally so that the restoration will appear more natural. By adhering to the aforementioned principles regarding mesiodistal, buccolingual, and incisogingival positioning of the peg-shaped lateral, proper esthetics can be achieved.

Occasionally, the team will treat a young patient with short clinical crown length. In this situation, the eventual clinical crown length of the anterior teeth must be established before restoring the malformed lateral incisor (Fig 6).

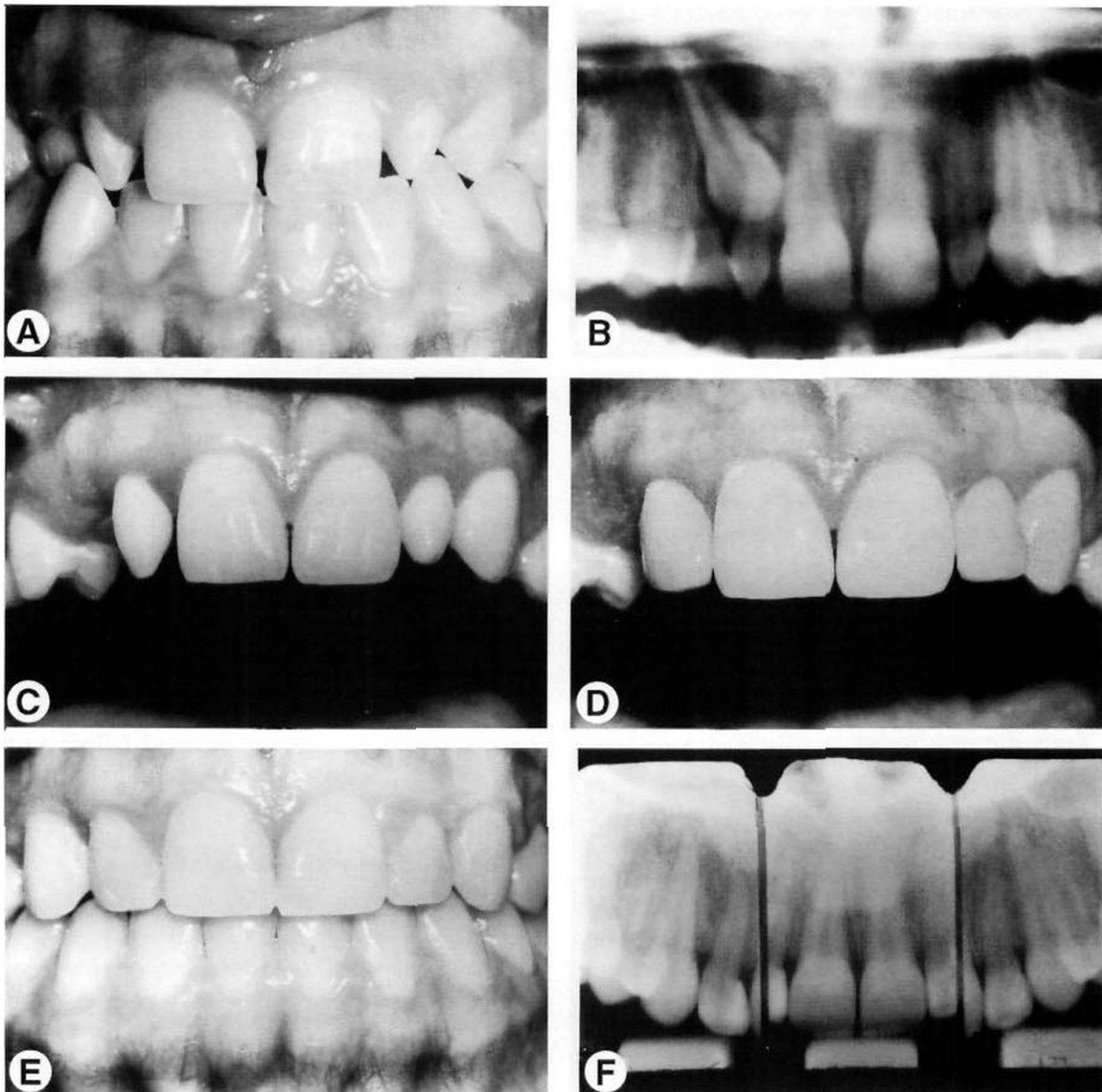


Figure 6. This patient had peg-shaped lateral incisors with short clinical crown length (A and B). A gingivectomy was performed (C) to provide crown length to temporarily restore the laterals (D) and facilitate orthodontic correction of the impacted canine (E and F).

In some young patients, the labial gingival margin has not migrated to its eventual adult level (about 1 mm from the cemento-enamel junction). If this situation exists, it may be difficult to create the proper crown length before orthodontic treatment. These patients require gingival surgery. By surgically moving the gingival margin to its appropriate level relative to the cemento-enamel junction, the peg-shaped lateral can be restored to more ideal length and shape. Either a gingivectomy or osseous surgery may be necessary. The decision of which procedure to use depends on the bone level.⁵⁻⁸ If the bone is located near the cemento-enamel junction, osseous surgery will be necessary to move the bone 1 to 2 mm away from the cemento-enamel junction. This will create the proper biologic width between bone and depth of the sulcus.⁹⁻¹¹ However, if the bone is 1 to 2 mm away from the cemento-enamel junction, a simple gingivectomy can be used to create proper contour of the gingival margins.

Position Teeth to Facilitate Restorative Treatment

In the nonrestored adolescent patient, orthodontic positioning of teeth is determined by the size and shape of the teeth. Ideally, if the sizes of all teeth are compatible, then a Class I occlusion with complete interdigitation is possible. However, in the orthodontic-restorative patient, it may not be prudent to position teeth ideally. If restorations are planned for the patient, it may be advantageous to position teeth to facilitate restorative treatment. Specific restorations require different types of tooth positioning.

Resin-Bonded Bridge

A popular restoration for replacing congenitally missing maxillary lateral incisors is a resin-bonded bridge. Although this type of restoration has a high incidence of failure caused by debonding,^{12,13} it is a conservative means of replacing a missing maxillary lateral incisor tooth until an implant can be placed at a later time. If the teeth are in proper position, the life of a resin-bonded bridge can be increased and the tendency for debonding may be decreased.

First, a resin-bonded bridge depends on surface coverage for retention. The greater the area of coverage on the lingual of the maxillary central incisor and canine, the greater the retention. It is therefore important to position the

anterior teeth with the appropriate overjet and overbite relationships. If the overjet at the end of orthodontic treatment is ideal, with the maxillary and mandibular incisors in contact, the amount of overbite should be minimized (Fig 7). The patient has sufficient overbite if the incisors are in contact when the mandible is protruded. If the overbite is minimized, a greater portion of the lingual surfaces of the maxillary central and canine can be covered with the bonded metal framework of the resin-bonded bridge, and the greater the surface area covered with metal, the greater the retention. If the overbite is deep at the end of orthodontic treatment, the amount of lingual coverage of the resin-bonded framework will be reduced and the retention will be adversely affected.

A second important factor in final positioning of the maxillary anterior teeth is the angulation of the central incisors and canines at the end of orthodontic treatment. If the maxillary central incisors are upright or oriented vertically relative to the mandibular arch, then the occlusal forces during incisor contact will be directed vertically or longitudinally through the root of the tooth. The latter is ideal. The resin-bonded framework will have better shear strength than tensile strength, when the forces are oriented vertically through the crown and root of the central incisor, and the retention of the resin-bonded bridge will be enhanced. However, if the orthodontist has proclined the maxillary central incisors, the occlusal force on the central incisor will be directed labially. As a result, the metal connector of the resin-bonded bridge on the central incisor could become dislodged. Teeth that are proclined during orthodontic treatment have a higher tendency for bond failure with resin-bonded bridges than are those in patients with more upright incisors and canines.

Anterior Conventional Bridge

Although implants and resin-bonded bridges are the most popular restorations for missing maxillary anterior teeth, occasionally a conventional bridge is appropriate. If patients have endodontically treated teeth or have had previous restoration or fracture of the maxillary incisors and canines, a conventional bridge may be the best treatment plan. If a conventional anterior bridge is planned, the orthodontist should create 0.50 to 0.75 mm of overjet at the end of orthodontic treatment (Fig 8). A conventional bridge will

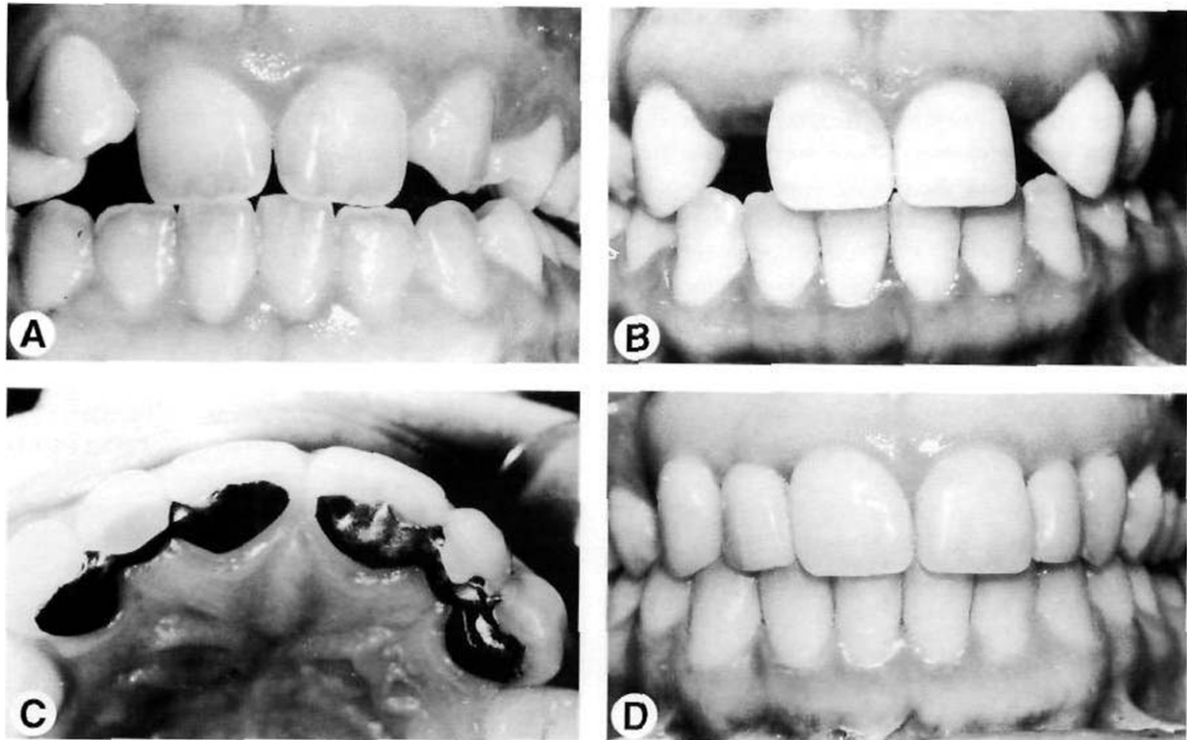


Figure 7. This patient was congenitally missing both maxillary lateral incisors (A). After space was opened orthodontically (B), a resin-bonded bridge was placed to restore the edentulous spaces (C and D). The amount of overbite was minimized to provide more surface area for the metal framework.

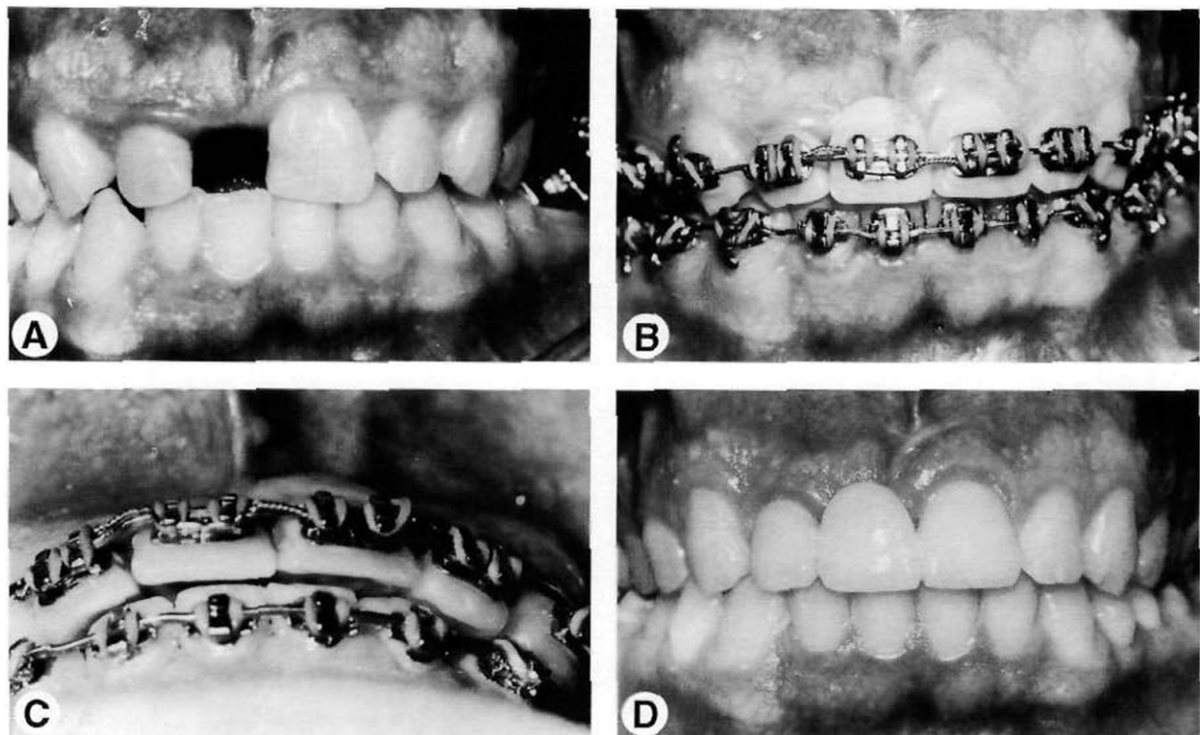


Figure 8. The maxillary right central incisor was avulsed in an accident (A). The left central and right lateral had been fractured, and a conventional bridge was planned. To provide space for porcelain and gold, a slight overjet was created during orthodontic finishing (B and C). This provided the restorative dentist with adequate space to place the three-unit anterior bridge (D).

require full crowns on the abutment teeth. Porcelain fused to metal crowns are thicker buccolingually than are natural teeth. If the orthodontist completes the orthodontic treatment with the incisors in contact, then more tooth structure must be removed on the lingual of the abutment to create space for porcelain and gold. In addition, the facial surface of the tooth may be moved labially relative to an adjacent nonrestored incisor. However, if a slight overjet remains after orthodontic treatment, the restorative dentist will use that space to create the correct thickness of the crown for the abutment teeth. To compensate for any lingual discrepancy

between a crowned and noncrowned incisor, composite can be bonded to the lingual of the nonrestored incisor to increase its thickness and create contact with the mandibular incisors.

Abraded Teeth

In some adult orthodontic patients, the maxillary and mandibular incisors have been worn or abraded. As attrition occurs, the teeth erupt. Eventually, the incisors will have shorter crown length than the adjacent unworn teeth. If the patient has a high lip line, this crown length discrepancy and gingival margin irregularity may be unesthetic (Fig 9). In these patients, it may be

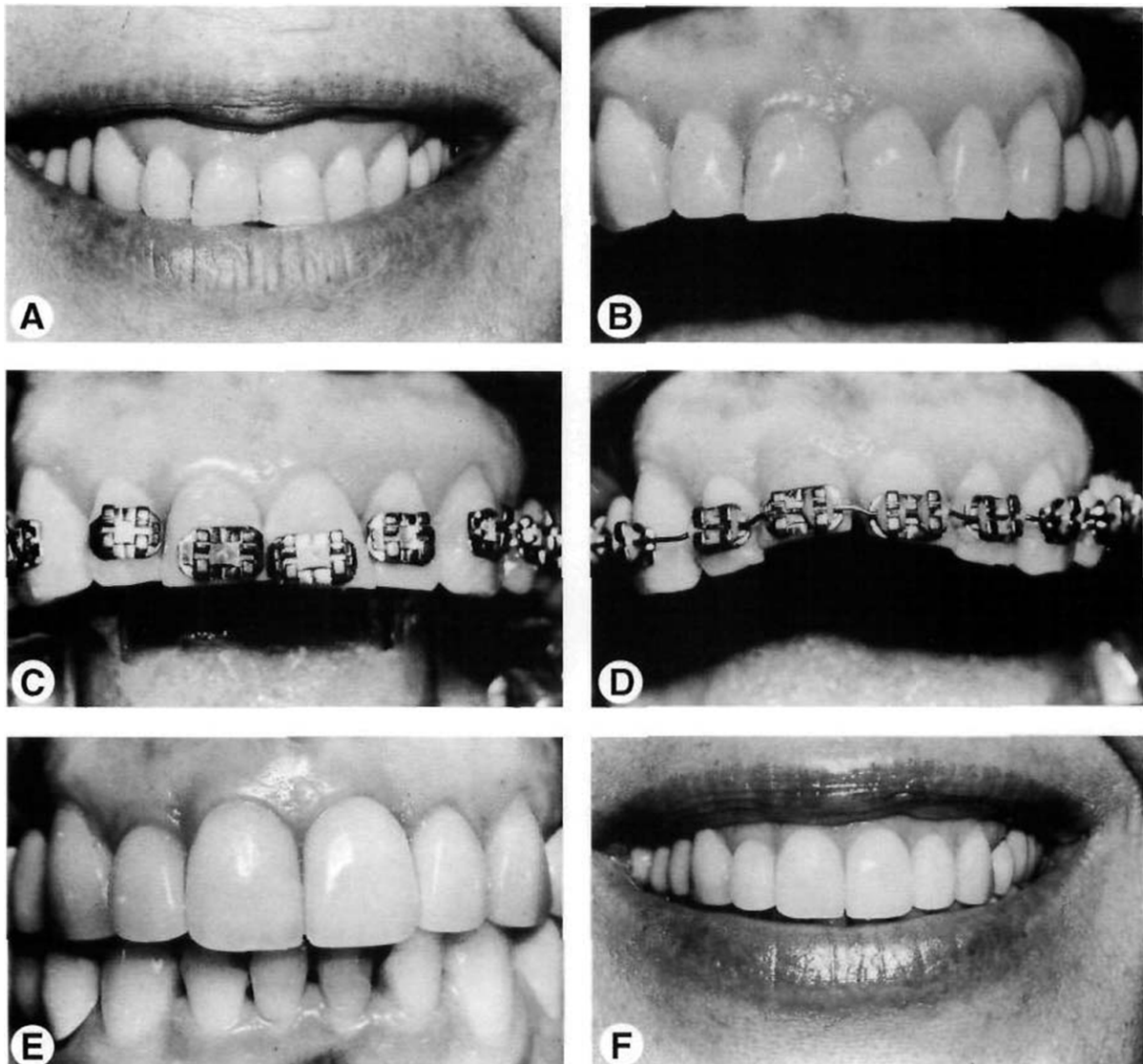


Figure 9. This patient had abraded central incisors and a “gummy smile” (A and B). To eliminate the “gummy smile” and improve the level of the gingival margins, the maxillary central incisors were intruded (C and D). By intruding the teeth, the restorative dentist could lengthen the incisors and eliminate the unesthetic “gummy smile” (E and F).

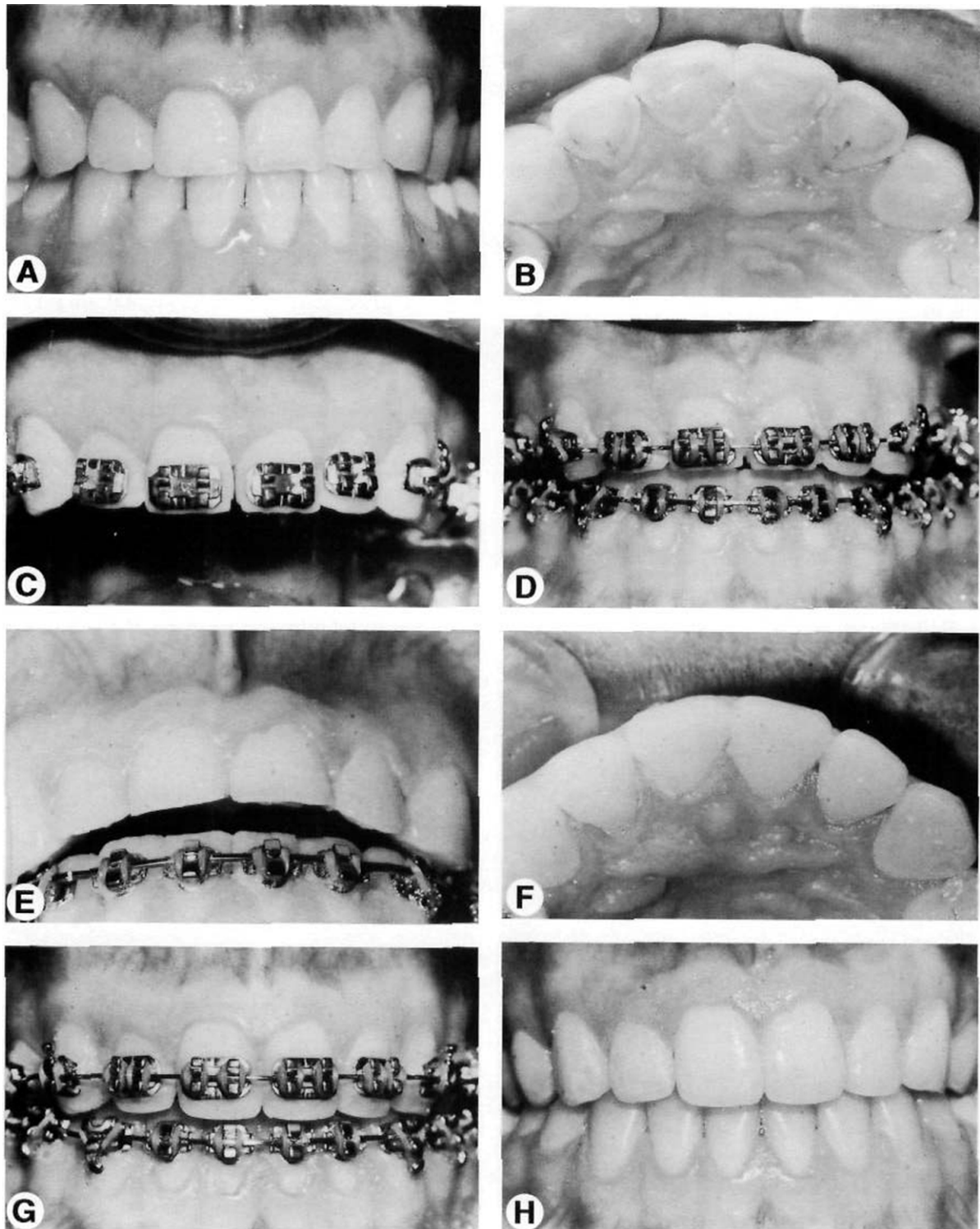


Figure 10. This patient was a bulimic. She had chemically abraded the lingual surfaces of the maxillary incisors (A and B). To provide space to restore the lingual surfaces of the maxillary incisors without preparing these teeth, the maxillary brackets were placed near the incisal edge (C). The posterior teeth were used as anchors to intrude the maxillary centrals and laterals to create restorative space (D and E). After intrusion the lingual surfaces of the maxillary anteriors were restored temporarily with composite (F). Brackets were replaced on the teeth and the final occlusion was established (G and H).

appropriate to intrude the worn or abraded teeth and restore the abraded surfaces during orthodontic treatment.¹⁴⁻¹⁸ Initially, the brackets on worn incisors should be placed nearer the incisal edges (Fig 9C). The objective is to level the gingival margins of the two central incisors. The gingival margins of the central incisors should match the level of the maxillary canines. The gingival margin of the lateral incisor should be positioned slightly coronally. By using the gingival margins as a guide, the anterior teeth will be intruded (Fig 9D). The posterior teeth are used as anchors to facilitate the intrusion of the maxillary and/or mandibular incisors. This creates an open-bite. After the appropriate gingival margin relationship has been achieved, the brackets should be removed, the incisal edges may be restored, and the brackets can be replaced to complete the orthodontic treatment. By intruding the incisors to overcome gingival margin and crown length discrepancies, the correct size relationship of the teeth can be achieved, and esthetics can be restored to the patient (Fig 9E and F).

In some patients, wear or abrasion may occur on the lingual surface as well as on the incisal edges. Occasionally patients will produce chemical erosion of the lingual surfaces of the maxillary incisors caused by bulimia (Fig 10). If the maxillary and mandibular incisors have maintained occlusal contact, it is important during orthodontic-restorative treatment to create restorative space. In these patients, restorative space may be established by intruding the maxillary or mandibular incisors. Some of these patients will also require adjunctive periodontal surgery to enhance the restoration of the teeth.

Occasionally, posterior teeth will wear significantly. If full crowns are planned for these teeth, it may be advantageous to intrude the worn teeth to provide space for the restoration (Fig 11). If severely abraded teeth are brought into occlusal contact during orthodontics, at least 2 mm of the occlusal surface must be removed to create space for the gold or gold and porcelain restoration. However, the patient may have already worn 1 to 2 mm off the occlusal surface. If additional enamel and dentin are removed, the lateral walls

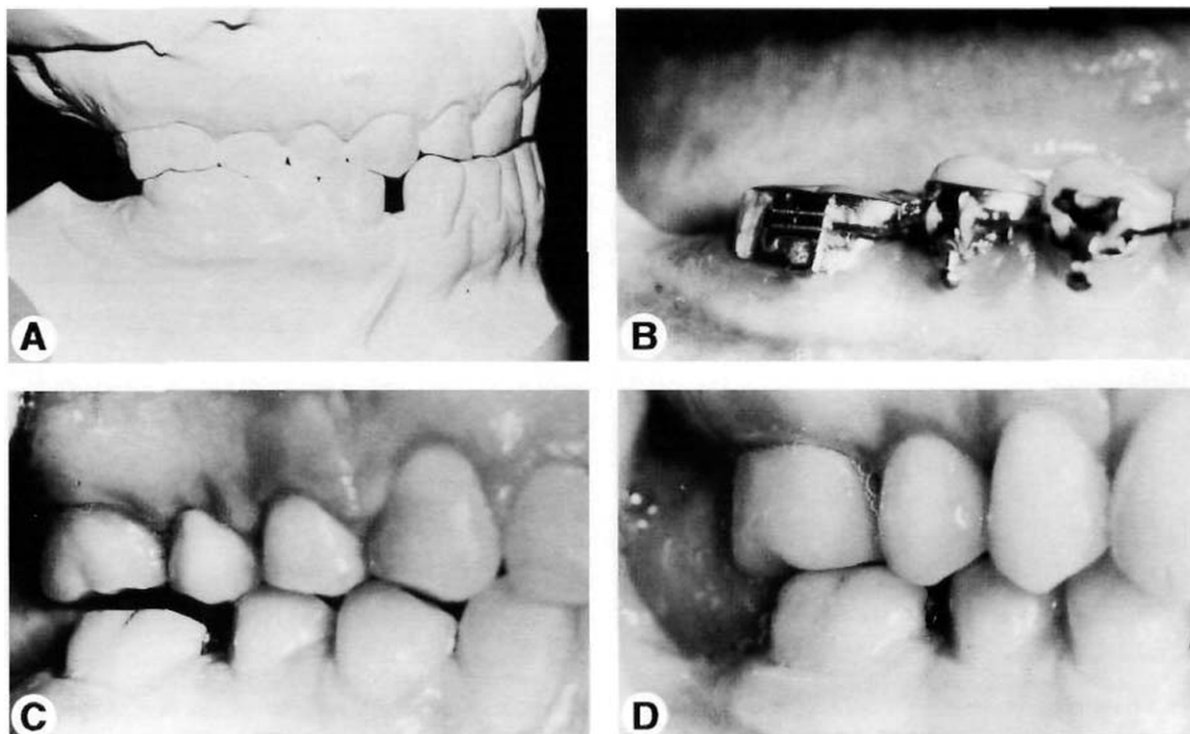


Figure 11. This patient had significant occlusal wear on the mandibular right first molar (A). This tooth required a full crown. To eliminate the need for occlusal reduction before crown preparation and enhance the retention of the crown, the molar was intruded during orthodontics (B and C). As a result, the tooth could be restored without preparing the occlusal or requiring crown lengthening of the first molar (D).

of the preparation may not provide adequate retention for the restoration. If the abraded molar is intruded, space will be created for the placement of gold and porcelain on the occlusal surface (Fig 11B and C). Then, when the tooth is prepared for the restoration, only the lateral walls need to be prepared. In this way, crown lengthening can be avoided, retention can be enhanced for the restoration, and the proper amount of space will remain for the occlusal portion of the restoration.

Evaluate Gingival Esthetics During Finishing

Some orthodontic-restorative patients will have crowns placed on their anterior teeth after orthodontic treatment. In these individuals, it is imperative that the gingival form and contour be evaluated and modified during finishing to produce the best esthetic result for the patient.

When assessing gingival form, the orthodontist should evaluate four criteria.^{15,17} First, the

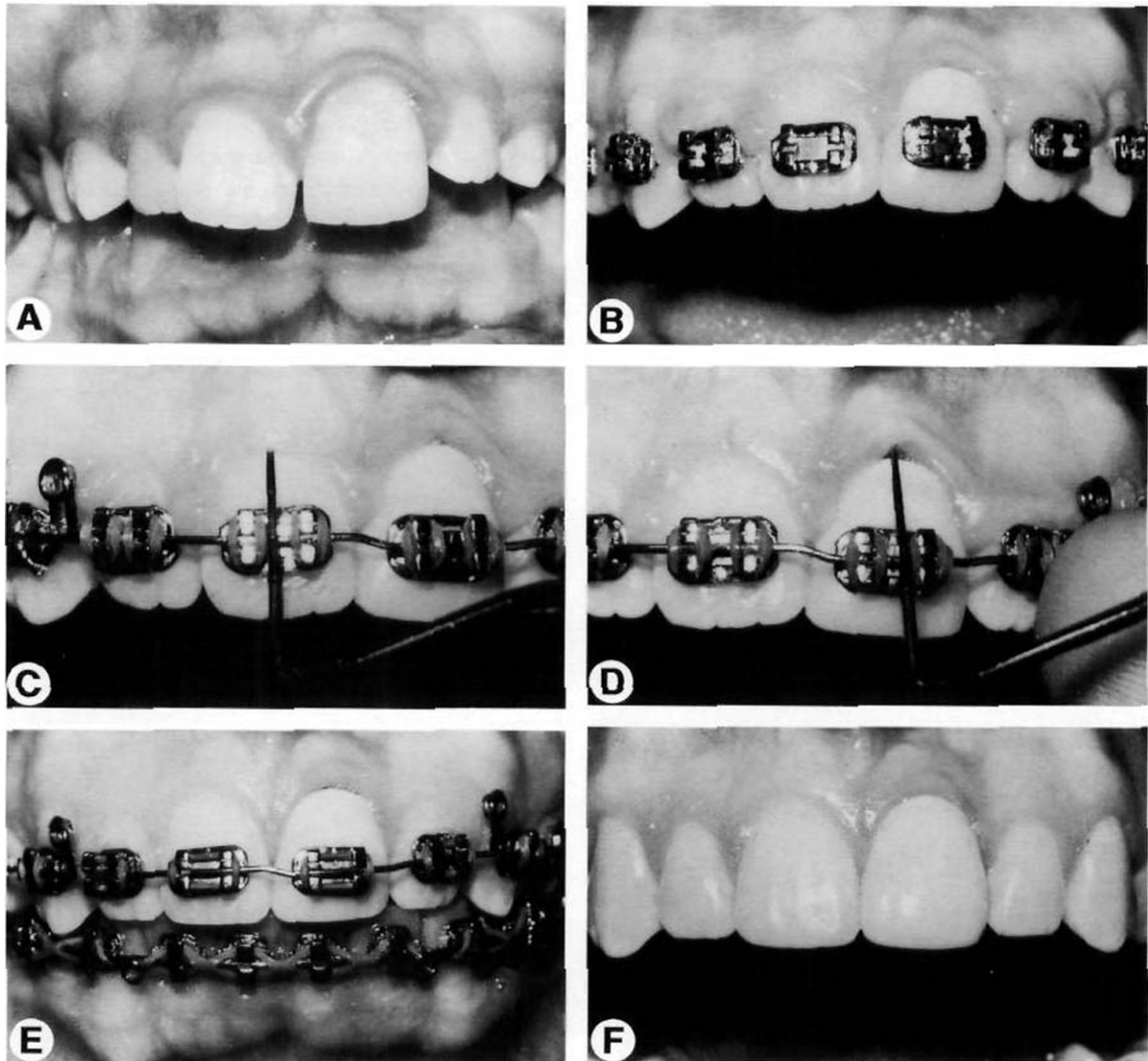


Figure 12. This patient had fractured the maxillary left central incisor and a crown had been placed at an early age (A). This produced a gingival margin discrepancy that persisted during orthodontic treatment (B). Evaluation of the sulcular depths revealed that a gingivectomy would be necessary to recreate normal gingival contours before bracket removal (C, D, and E). The gingivectomy was performed during orthodontics, and the final crown shows the benefit of creating proper gingival esthetics before final restoration (F).

gingival levels over the two central incisors should be at the same height. Second, the gingival margin over the lateral incisor should be positioned about 0.50 mm coronal to the central incisor. The gingival margin of the canine should be at the same height as the central incisor. The third aspect to evaluate is the contour of the labial gingival margin of each tooth. The gingival contour should follow the contour of the cemento-enamel junction. The last criterion to evaluate is the interproximal papilla. Ideally, tooth contact forms half of the interproximal contact and the papilla forms the other half. If any of these parameters are incorrect (Fig 12), and the patient will require restorative treatment after orthodontics, it is important to correct the gingival discrepancies before bracket removal.

To identify a problem with gingival form, the orthodontist should probe the labial sulci over the maxillary anterior teeth. If the teeth have greater than 1 mm of sulcular depth (Fig 12C), and the gingival margins are at different levels, the patient should be referred to a periodontist to perform gingival surgery to create more ideal

gingival form before bracket removal (Fig 12E). It is important to have the surgery done while the orthodontic appliances are still in place. In that way, if the gingival margins are not ideal after healing, the orthodontist can intrude or extrude teeth that will be restored to level any minor discrepancies in the gingival margins. In this way, the most ideal result will be achieved.

Take Radiographs During Finishing

In most orthodontic patients, aligning the crowns of the teeth will produce proper root angulation. Ideally, the roots of the teeth should not be in close interproximal contact. In that way, sufficient bone will be present between the roots of each of the teeth. Proper root angulation may be even more important for the orthodontic-restorative patient. When implants are planned for missing maxillary lateral incisors, it is important to create adequate space for the implant between adjacent roots. As the central incisor and canine are pushed apart, the apices of the roots move toward one another (Fig 13A and B).

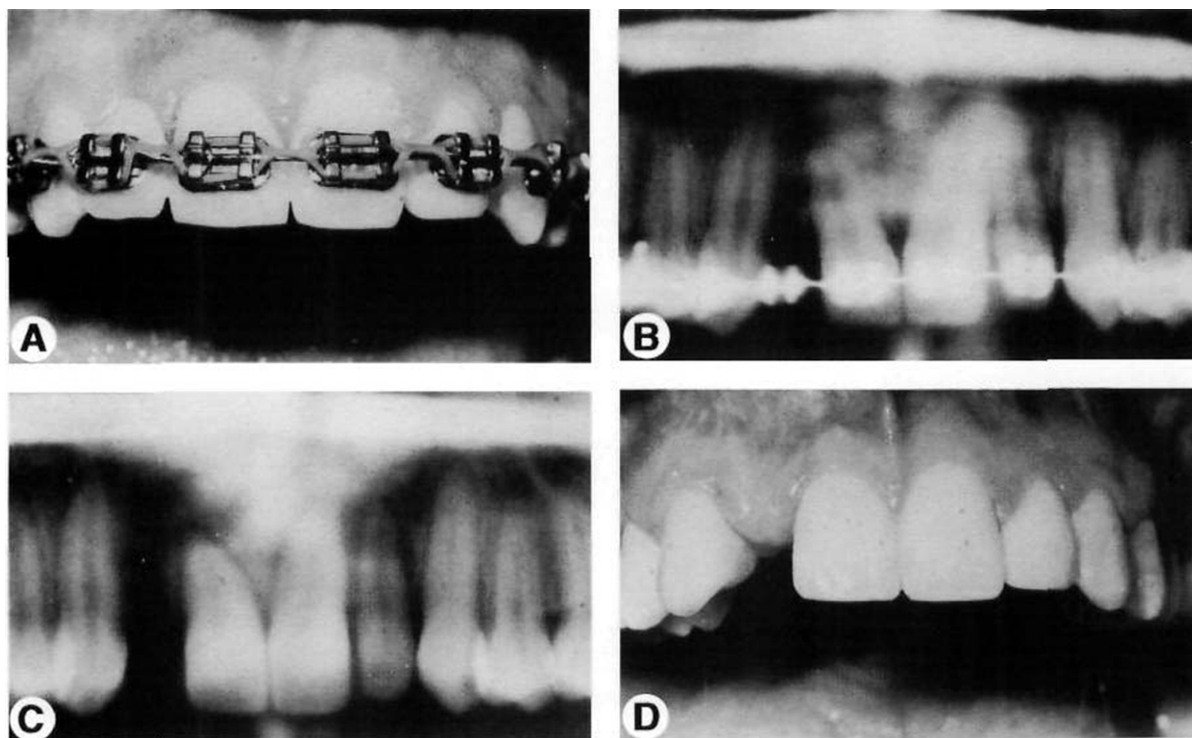


Figure 13. This patient is congenitally missing the maxillary right lateral incisor (A). An implant was planned for this space, however a radiograph before finishing showed that the roots were in close proximity (B). An additional 6 months of orthodontics was required to correct root angulation (C and D). Evaluation of periapical radiographs before bracket removal is important in patients who will require single-tooth implants.

During orthodontic finishing, radiographs must be taken to assess whether or not proper root angulation has been achieved. If not, the archwire must be removed and the teeth should either be rebracketed or bends placed in the archwire to achieve proper root angulation. If the roots are too close together, an implant cannot be placed.

Occasionally, a patient may have had restorations placed before orthodontic treatment. If the patient had malaligned teeth, the restored crowns and roots may be angulated unusually (Fig 14A and B). In these types of patients, it is important

to take radiographs during orthodontic finishing to ensure that the root of the tooth is positioned properly so the crown may be restored correctly after orthodontic appliances have been removed (Fig 14C-F).

Interact With the Restorative Dentist

If an orthodontic patient will not have any restorations, it is appropriate that the orthodontist makes the final decisions regarding tooth position and appliance removal. However, if

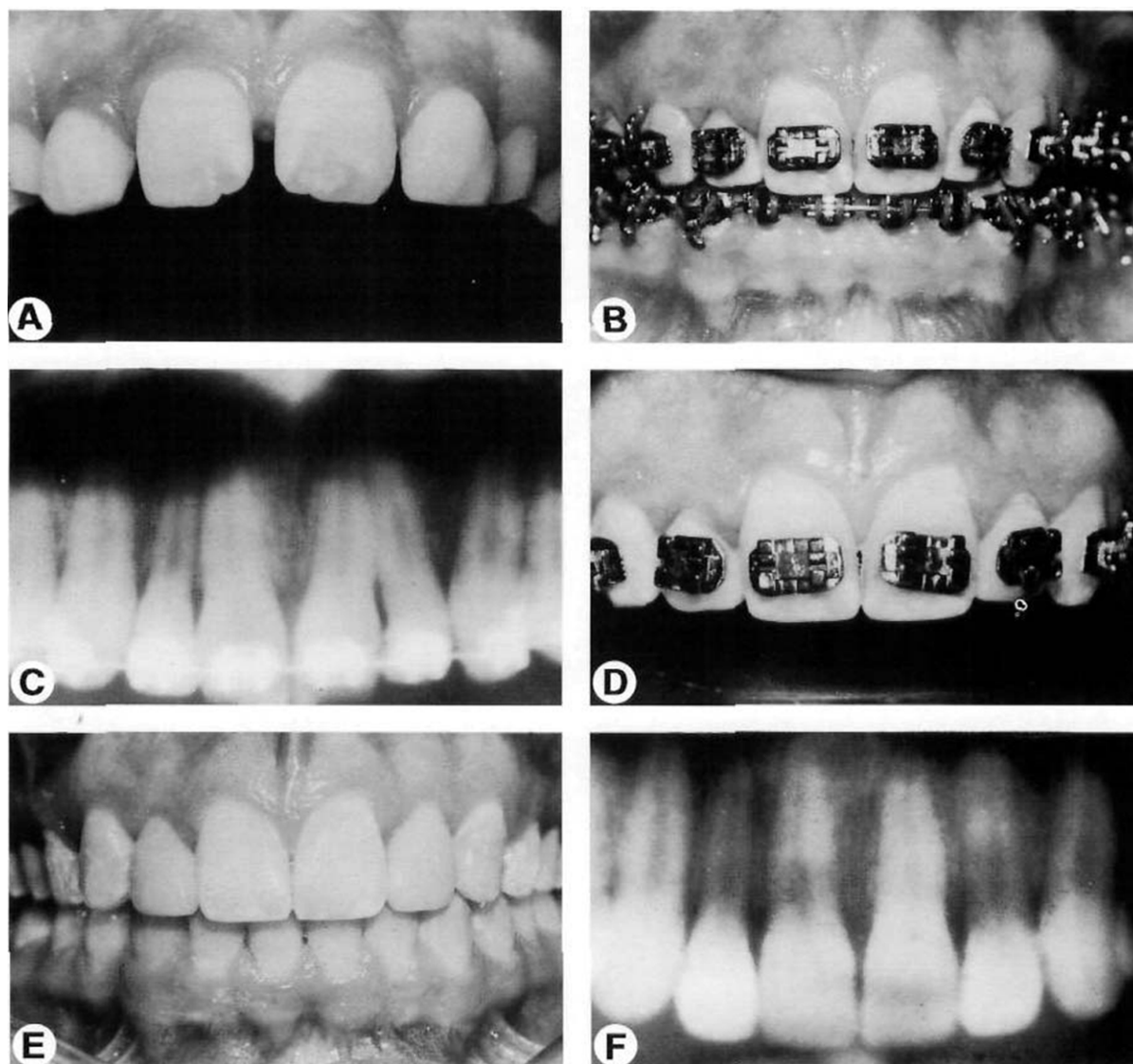


Figure 14. This patient had peg-shaped maxillary lateral incisors. These teeth had been restored before orthodontic therapy (A). During orthodontic finishing, (B) a progress panoramic radiograph was made (C). The radiograph showed that the roots of the teeth did not reflect the position of the incisal edges of the crowns. The teeth were rebracketed (D) and the roots were aligned properly (F). By aligning the roots properly, the esthetic appearance of the restorations could be enhanced (E).

patients will require restorations after orthodontics, the restorative dentist should play a part in the finishing process. It is not prudent for an orthodontist to neglect the restorative dentist during finishing. It is advantageous to request input from the restorative dentist during final tooth positioning. Refer the patient back to the restorative dentist during the final 6 months of treatment. Send a note or letter asking for input from the restorative dentist about final tooth positioning, especially in areas where restorations are planned. Not only does the patient benefit from having several individuals evaluate the final result, but the orthodontist will learn from this interaction about the individual requirements of certain types of restorative patients. In addition, the restorative dentist will be more aware of the treatment possibilities for the orthodontic-restorative patient.

Summary

This article has described eight guidelines to assist clinicians when planning interdisciplinary treatment. If orthodontists and restorative dentists establish realistic objectives, create a diagnostic set-up, determine the sequence of treatment, build-up malformed teeth, position teeth to facilitate restorative treatment, evaluate gingival esthetics, take progress radiographs, and interact during finishing, the esthetic and occlusal outcome of their combined efforts will be greatly enhanced.

References

1. Carlson G. Changes in contour of the maxillary alveolar process under immediate dentures. *Acta Odont Scand* 1967;25:1-31.
2. Ostler MS, Kokich V. Alveolar ridge changes in patients congenitally missing mandibular second premolars. *J Prosthet Dent* 1994;71:144-149.
3. Kokich V. Enhancing restorative, esthetic and periodontal results with orthodontic therapy. In: Schluger S, Youdelis R, Page R, et al, editors. *Periodontal Therapy*. Philadelphia: Lea and Febiger, 1990:433-460.
4. Kokich V. Anterior dental esthetics: An orthodontic perspective III. Mediolateral relationships. *J Esthet Dent* 1993;5:200-207.
5. Orban B. Indications, technique and postoperative management of gingivectomy in the treatment of periodontal disease. *J Periodontol* 1941;12:88-91.
6. Goldman H. The development of physiologic gingival contour by gingivoplasty. *Oral Surg* 1950;3:879.
7. Ramfjord S. Gingivectomy—its place in periodontal therapy. *J Periodontol* 1952;23:30-35.
8. Prichard J. Gingivectomy, gingivoplasty, and osseous surgery. *J Periodontol* 1961;32:257-262.
9. Garguilo A, Wenz F, Orban B. Dimensions and relation at the dentogingival junction in humans. *J Periodontol* 1961;32:261-267.
10. Maynard J, Wilson R. Physiologic dimension of the periodontium fundamental to successful restorative dentistry. *J Periodontol* 1979;50:170-174.
11. Wilson R, Maynard J. Intracrevicular restorative dentistry. *Int J Periodont Restor Dent* 1981;4:35-50.
12. Creugers N. Seven year survival study of resin-bonded bridges. *J Dent Res* 1992;71:1822-1825.
13. Boyer D. Analysis of debond rates of resin-bonded prostheses. *J Dent Res* 1993;72:1244-1248.
14. Kokich V, Nappen D, Shapiro P. Gingival contour and clinical crown length: Their effects on the esthetic appearance of maxillary anterior teeth. *Am J Orthod* 1984;86:89-94.
15. Kokich V. Anterior dental esthetics: An orthodontic perspective I. Crown length. *J Esthet Dent* 1993;5:19-23.
16. Kokich V. Anterior dental esthetics: An orthodontic perspective II. Vertical relationships. *J Esthet Dent* 1993;5:174-178.
17. Chiche G, Kokich V, Caudill R. Diagnosis and treatment planning of esthetic problems. In: Pinault A, Chiche G, editors. *Esthetics in Fixed Prosthodontics*. Chicago, IL: Quintessence, 1994:33-52.
18. Kokich V. Esthetics: The ortho-perio-restorative connection. *Semin Orthod* 1996;2:21-30.