

Maxillary development revisited: relevance to the orthopaedic treatment of Class III malocclusions*

Jean Delaire

UER des sciences et techniques médicales of Nantes, France

SUMMARY Normal development of the maxilla results not only from movements of its constituent skeletal units and bony apposition–resorption superficially, but also from the specific development of the antero-lateral regions. In Class III cases, correction of the skeletal dysmorphosis requires not only that the maxilla is in a correct position (in relation to the mandible) and that the correct occlusion is achieved, but also that there is good development of the exo-peri-premaxilla. This requires normalization of muscular posture (labio-mental, lingual, velo-pharyngeal) and of orofacial functions (nasal ventilation, swallowing, mastication). Postero-anterior traction using an orthopaedic mask can only accomplish part of the treatment of Class III. The action must always be complimented by other therapy aimed at correcting the underdevelopment of the antero-lateral regions. Facemask therapy is not only simple sagittal distraction, but is truly a method for treatment of Class III which is well understood and achieves excellent results. Taking into account the great diversity of anatomical forms of Class III malocclusion, it is not surprising that extra-oral postero-anterior traction gives widely varying results. The quality, however, depends principally on the method used. Orthodontists must not hesitate to call for the assistance of a surgeon each time the functional treatment is insufficient, particularly in cleft patients where the results depend more on surgical procedures, both primary and secondary, than on dentofacial orthopaedics.

Introduction

In 1971, a paper was presented to the European Orthodontic Society (Delaire, 1971) in which the following were stressed: the role of the sutures, cartilage, muscles and orofacial functions in facial development; the specific development of the premaxilla and the upper dento-alveolar arch; the involvement of the sinus in maxillary development; the inadequacy of conventional cephalometry, and the need for a new method of analysis which would be able to assess cranio-facial development and the real effects of orthopaedic treatment.

Since that time, the effects of orthopaedic forces have been demonstrated in animals, on dry or macerated human craniums, and in the clinical situation.

Animal experiments and histological studies have been able to show, in particular: the

identical structure and physiology of sutures and dento-alveolar ligaments (Lebourg and Seydel, 1932; Scott, 1967); the potential for activity in the sutures after puberty (although increasingly less in older animals); the different effects of traction on the maxilla depending on the points of application and orientation in different situations; sagittal displacement, maxillary rotation, and variations of the centre of rotation; the effects of maxillary traction on the cranial base and vault (Jackson *et al.*, 1979), and on the synchondroses and sutures which separate them, the adjacent superficial periosteum and the same more distantly, on the inner and outer surfaces of the skeletal units. On dry or macerated human skulls, and on photoelastic models, it has been demonstrated that orthopaedic forces produce the same mechanical effects as those obtained in animals.

In the clinical situation, studies on the effect of traction in the treatment of Class III have demonstrated the following: maxillary skeletal

*Sheldon Friel Memorial Lecture

protraction, forward movement of the maxillary dentition, set back of the bony menton, augmentation of facial height, and lingual tipping of the lower incisors (Delaire, 1971, 1976, 1990; Verdon, 1974; Irie and Nakamura, 1975; Vego, 1976; Cozzani, 1981; Baumrind *et al.*, 1983; Salagnac *et al.*, 1983; McNamara, 1987; Sarnäs and Rune, 1987; Mermigos *et al.*, 1990).

However, it has also been shown that these results vary according to the age of the patient, and the force, orientation and duration of the application of traction.

Furthermore, it has been demonstrated that traction promotes extrusion of the upper molar teeth (this limits its use in the treatment of Class III malocclusions with a vertical facial excess), as well as angulation of the incisors, and also that it is less effective in the Class III situation as found in labio-maxillo-palatine clefts.

As part of treatment, a number of orthodontists currently use not only the orthopaedic mask to apply postero-anterior extra-oral traction to treat Class III malocclusions, but also obtain good results with its use. Conversely, infrequent use often results in a poor outcome.

Why are there differences?

There are four possible explanations:

1. There are different types of Class III—the same occlusion comes associated with very different skeletal anomalies.
2. There are certain peculiarities in maxillary development in humans, and it is necessary to take these into account in dentofacial orthopaedic treatment.
3. The major role of dysfunctions in determining dentofacial dysmorphism, and in particular Class III, and the necessity, simultaneously and as an integral part of treatment, to correct both (dysfunctions and skeletal anomalies), is something that is not always carried out.
4. The inadequacy of conventional cephalometric techniques which do not permit correct diagnosis of skeletal anomalies, and therefore specific treatment.

Variations in Class III

Class III malocclusions can result from a combination of a number and variety of anomalies of the facial skeleton, dento-alveolar structures, and the cranium (Enlow, 1968; Enlow *et al.*, 1977; Delaire, 1976; Ellis and McNamara, 1984; Guyer *et al.*, 1986).

The current classification, as shown below, is inadequate:

- A prognathic mandible, maxilla normally positioned;
- B retrognathic maxilla, mandible normally positioned;
- C maxilla and mandible normally positioned;
- D retrognathic maxilla, prognathic mandible.

Taking into account the height of the face, and considering the following five principal factors—the position of the maxilla, the mandible, the maxillary alveolus, the mandibular alveolus, and vertical development—and giving to each three possible values (plus, zero and minus), Ellis and McNamara (1984) have calculated that 243 possible combinations exist, of which only 69 varieties were observed in 302 adults examined. In addition, a number of other factors are involved, including: protrusion and retrusion of the teeth; the orientation and height of the maxilla; the length and orientation of the ramus and body of the mandible and the mandibular angle, and the cranial base and vault, and the neck (Solow and Tallgren, 1971; Delaire, 1980).

It is apparent that there are yet still more possible combinations. There are, therefore, a large number of anatomical-clinical varieties in the 'syndrome prognathique' (Delaire, 1976). In reality, each person presents with an individual type of Class III which can respond individually and differently to the same treatment.

It must be noted that most of the studies on the malformations associated with Class III have been carried out on adults, when it has been apparent that a surgical procedure to set back the mandible is not always indicated and that a maxillary advancement is preferable. The same combination of anomalies may also be found in children, where however they are usually less

severe and with proportionally less mandibular protrusion (Graber, 1969; Guyer *et al.*, 1986).

With extra-oral traction, the orthodontist now has the possibility of advancing the maxilla during development and must, like the surgeon, be well acquainted with all the anomalies needing treatment, and must also fully appreciate the aetiopathogenesis of these anomalies and the capacity for improved development with orthopaedic treatment.

The development of the maxilla

Consideration of classic concepts

It is currently believed that maxillary development results solely from two phenomena: the 'en bloc' displacement of the maxillary skeletal components, and superficial bony apposition-resorption. This superficial apposition occurs, however, in the region of the tuberosities and of the palatal vault. In the anterior part of the maxilla, there is no apposition (Enlow, 1968; Enlow and Bang, 1965; Enlow *et al.*, 1977), but rather resorption (Björk and Skieller, 1977). Typically, as sagittal development of the maxilla is therefore exclusively due to its displacement forwards and to compensatory activity of the sutures, then only postero-anterior traction can move it.

However, many authors assume that there exists, in addition, a specific development of certain constituent parts of the maxilla, with two separate parts of the facial skeleton which differ in development: the anterior face (or 'exoface') and posterior face ('endoface' or 'mesoface') (de Coster, 1952; Delattre and Fenart, 1960; Moss and Young, 1960; Moss and Greenberg, 1967; Scott, 1967; Fenart, 1985).

It has also been suggested that the relatively autonomous development of certain parts of the maxilla, the dento-alveolar arch, the maxillary sinus, and the premaxilla respond differently to treatment (Delaire, 1971, 1989, 1990), and that individual treatment plans should be devised.

Since that time, the existence of these specific areas of development in the anterior maxilla, and of poorer development of these areas in many patients with a Class III skeletal discrepancy, has been stressed by other authors. The

term 'Class III' is currently used when the molar occlusion is subnormal, when there is an anterior malocclusion due to incisivo-canine palatal tilt, or even when there is an edge-to-edge incisor occlusion.

The existence of specific areas of development in the anterior maxilla should be carefully examined in relation to the aetiopathogenesis and treatment of Class III. However, two questions must be answered.

The first question is: How can the anterior maxilla develop in the absence of movement of the skeletal units and without superficial bony apposition? If a specific type of development does exist, why can it not be quantified in the usual cephalometric analysis and the method described by Björk, using metallic implants?

With regard to the first point, the response is: 'because the maxilla is a membranous bone' and therefore has a particular manner of development. This is especially noticeable in the cranial vault. This bone develops not only by compensatory ossification of the sutures which separate them, and by superficial bony apposition-resorption, but also by progressive expansion (separation) of the external and internal bony cortices (Figure 1). This has been known for a long time (Weidenreich, 1924; Augier, 1931). In 1891, Topinard wrote: 'The cranium is formed by two independent layers, not under the same physiological influences, sometimes touching, sometimes separated by a layer of spongy tissue with abundant diploe, supplemented by compact bone in regions where it protrudes, sometimes with wide spaces between them, with sinuses, as at the base of the forehead where the sinuses reach sometimes the frontal bumps. Attached to the outer layer are muscles and ligaments which encourage denser bone to develop, although this to some extent depends on the patient's stature. Whilst the inner layer is governed by the brain, external factors are more important for the outer layer.'

Moss and Young (1960) have also commented on the same factors: 'we may grossly divide the skull into "neural" and "facial" components, which separately respond to neural and visceral function. . . . The adult human frontal bone, in common with all other calvarial bone, consists

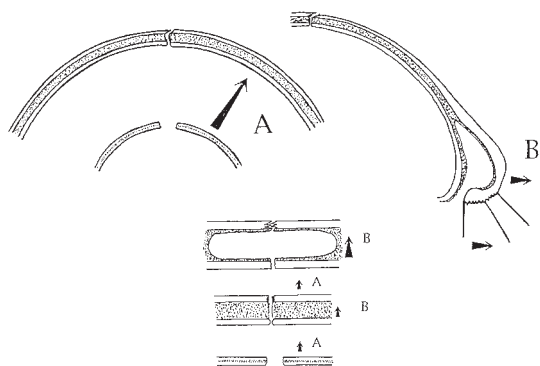


Figure 1 Membranous bones of the cranial vault increase in size by (A) 'en masse' movement of the skeletal constituents; (B) specific movement of the external cortex, and to a lesser extent by a superficial apposition-resorption of bones.

of an inner and outer plate of compact bone, and an intervening mass of simple trabeculae. . . . A centrifugal gradient of this bone into a thicker, though still porous tissue mass, is followed by the production of the three-layered structure. . . . Prior to the formation of diploe and plates, the entire bone is related to the brain alone. . . . The gradual differentiation of the outer plate is correlated with the increasing demands of the scalp tissues in general, and of the calvarial muscles in particular. . . . The inner table of the frontal bone is functionally associated with the development of the frontal lobe of the cerebral cortex. . . . The result of this osseous differentiation is to dissociate functionally the two plates of bone with the appearance of intervening diploe. . . . We may safely conclude that the form of the ectocranial surface of the neurocranium is functionally unrelated to that of the endocranial surface.'

In the first month of life, these cortices are very close to each other (de Coster, 1952; Moss and Young, 1960). With the passage of time, they thicken and become increasingly separated by a layer of diploe and, in certain circumstances, by a cavity, for example the frontal sinus. There are two types of cortical sutures: the external sutures, which are serrated, are subjected to greater distension than the internal sutures due to the curvature of the cranium and the mechanical effects of the temporal and occipital muscles which are inserted on the external

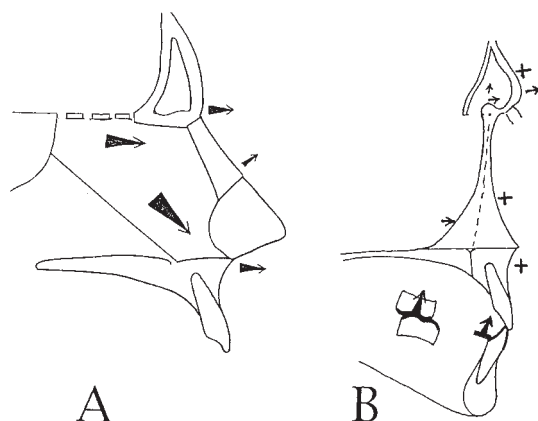


Figure 2 Factors responsible for the syndesmosis of the frontal cortices (and for development of the frontal sinus). (A) Forward push of the septal cartilage which occurs in the sagittal plane and (B) occlusal forces on both sides of the median line.

surface of this bone. Their development is therefore greater and thus close much later.

In infants, three phenomena (*en bloc* displacement of skeletal units, superficial bony apposition-resorption, and expansion and thickening of the external bony cortices) occur simultaneously, but their importance varies with age and region. Typically, up to 3-4 years there is a very active period of cerebral expansion, and development of the vault is principally due to '*en bloc*' displacement of these parts of the skeleton; after 4-5 years, movements of the external cortices play an increasingly important role. At the union of the vertical and horizontal parts of the frontal bone, the cortical separation is responsible for development of the frontal sinus.

Part of the anterior cranial base, from the pituitary point to the foramen caecum, acquires definitive dimensions between the ages of 6 and 8 years (Augier, 1931; de Coster, 1952; Moss and Young, 1960; Moss and Greenberg, 1967; Scott, 1967; Enlow, 1968). After this age, the anterior cranial base develops exclusively in front of the foramen caecum. According to Scott (1967), at 3 years the nasion is 5 mm in front of the foramen caecum and, by 20 years, between 15 and 20 mm. Ford (1958) found the distance between foramen caecum and the nasion somewhat less, being 6.9 at 2-6 years, 7.9 mm between 6 and 8 years, 9.6 mm between 8 and 14 years, 11.9 mm between 14

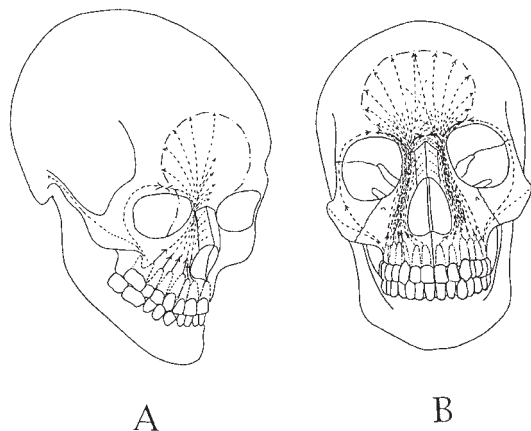


Figure 3 Schematic representation of the occlusal forces extending from the teeth to the forehead.

and 20 years, and 14.9 mm in adults. The factors responsible for this disjunction are essentially the forward push of the medial septal cartilage and occlusal forces (Figure 2). The role of the septal cartilage is well understood (Augier, 1931; de Coster, 1952; Delaire and Précious, 1987).

The importance of occlusal forces is less well considered. Maresh (1940) stated 'they are important from the point in time when the deciduous dentition is functional at about the age of two years'. According to Brown *et al.* (1984), between 2 and 3 years the frontal sinus begins higher than the line S–N. From 3–4 years, when the deciduous dentition is complete, they are transmitted through the maxillary buttresses to the anterior cortex of frontal bone, promoting its forward movement. In the mixed dentition, and subsequently the permanent dentition, the forces coming from the pre-orbital part of the upper jaw are transmitted 'from the teeth to the forehead' (Van der Klaauw, 1946) (Figure 3), so accentuating 'the dynamic expansion and the height of the frontal sinus' (Weidenreich, 1924).

Unlike the external cortex, the internal cortex lies in contact with the frontal lobes whose development is almost complete by the age of 3–4 years. After this age, the anterior part of the cranial base elongates exclusively in front of the foramen caecum, essentially at the level of its frontal segment to the base of the frontal sinus. In the course of this forward movement, the

external cortex of the frontal bone takes with it the nasal bones, including the nasion, and the upper extremities of the maxillary processes that united them to the fronto-maxillary suture. Depending on the intensity and orientation of the occlusal forces, the upper extremities of the maxillary processes can, however, have a different relationship to the base of the frontal sinus. In Class III malocclusions, there is often some underdevelopment of the frontal sinuses and the fronto-maxillary articulation may be more posterior.

The second question is 'Why is it not possible to assess, using conventional cephalometric analysis and Björk's metallic implants, the specific development of the antero-lateral part of the face?' This is because the classic points of reference and metallic implants used to measure this development are located on or implanted in the external cortex of the frontal bone and/or the maxilla and move at the same time.

It is especially important to note that the nasion, situated on the external cortex of the frontal bone, normally advances at the same time and in the same way as point A and ANS, which in turn lies on the anterior cortex of the maxilla. In the same way, the metallic implants, placed into the anterior cortex of the maxilla, move with it. This is true of the anterior metallic implants sited below the anterior nasal spine, and of the lateral implants placed in the zygomatic processes of the maxilla bony components which equally are part of the 'antero-lateral face' and are displaced with it. At this level, there does not exist the phenomenon of apposition–resorption (the reason for this has not been determined).

Maxillary development reviewed

The development of the superior maxillary bones, like those of the cranial vault, is not due only to 'en bloc' displacement of the maxilla (with compensatory ossification of the circum-maxillary sutures) and of superficial apposition–resorption, but also to specific development in the antero-lateral regions. The importance of these three factors is, however, variable, depending on the direction of development (sagittal, vertical or transverse) and the age of the patient. This can be summarized as follows:

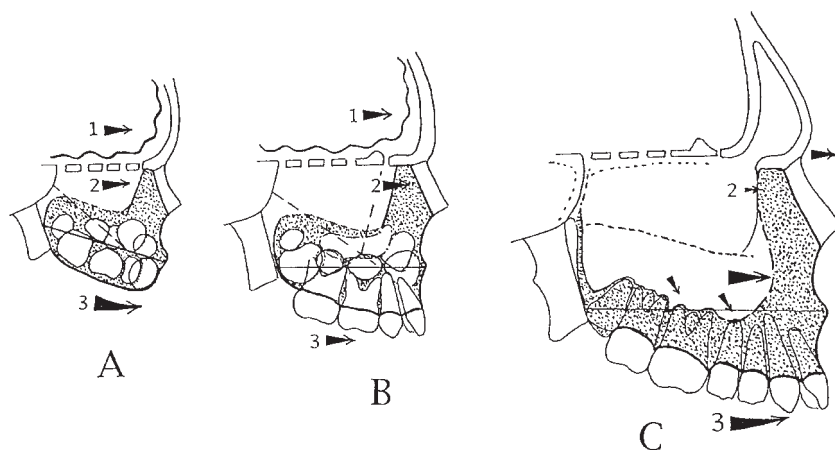


Figure 4 Schematic representation of maxillary growth in the sagittal plane. (A) 0–1 year of age; (B) 1 to 3–4 years of age; (C) after the age of 11–12 years. From birth to 3–4 years, the maxilla is displaced 'en bloc' with the frontal bone (from which it hangs) under the influence of pressure exerted from the posterior aspect in an anterior direction by the frontal lobes as they expand and the cartilages of the anterior part of the cranial base, the nasal capsule and median septal cartilage. From the age of 3–4, pressure on the frontal lobes has ceased. Forces created by the median cartilaginous septum and occlusion result in the separation and forward movement of the anterior cortex of the frontal bone which in turn induces movement of the maxillary processes. After 11–12 years of age, the premolars and second molars move away from the maxillary sinuses. The main development of the maxilla occurs in the antero-lateral parts, dependent on specific movements of the external cortices.

Sagittal plane (Figure 4). In the first years of life, the maxilla is displaced 'en bloc' with the frontal bone (from which it hangs) under the influence of pressure exerted posteriorly in an anterior direction, by the frontal lobes as they expand, and the cartilage of the anterior part of the cranial base, the nasal capsule and median septal cartilage.

From the age of 4–10, the maxilla moves forward in association with the anterior cortex of the frontal bone. To these forces are added pressure from the nasal capsule and the median septal cartilage against the nasal bones, and the forces from the facial superficial musculo-aponeurotic complex on the anterior nasal spine and premaxilla (Delaire and Précious, 1987). Pressure of the tongue against the palatal vault and occlusal forces on the upper dental arch contribute to these movements, and also to the development of the antero-lateral part of the maxilla (Figure 5).

At 11–12 years of age, maxillary development occurs in the antero-lateral parts depending on specific movements of the external cortices.

It should be noted that sagittal movements of the maxilla are normally accompanied by a

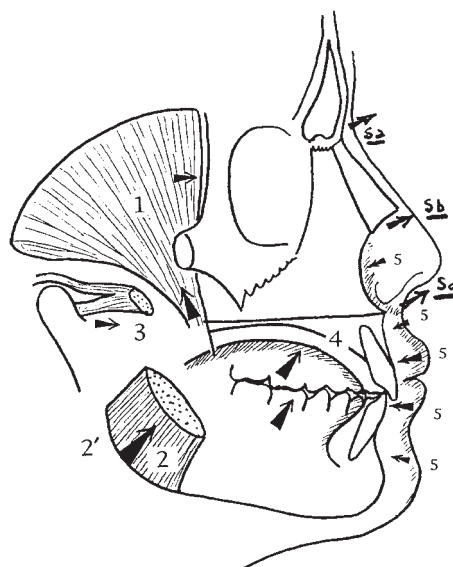


Figure 5 Factors responsible for the development of the whole maxilla from 3–4 years of age: masticatory muscles (1: temporal; 2 and 2': masseter and medial pterygoid; 3: lateral pterygoid), tongue (4), muscles of the superficial envelope (5), occlusal forces (6), mandibular growth forces (7), cartilaginous nasal septum: upper part just under the frontal sinus (Sa), mid-part under the nasal bones and (Sb), lower part where the nasio-labial muscles insert (Sc).

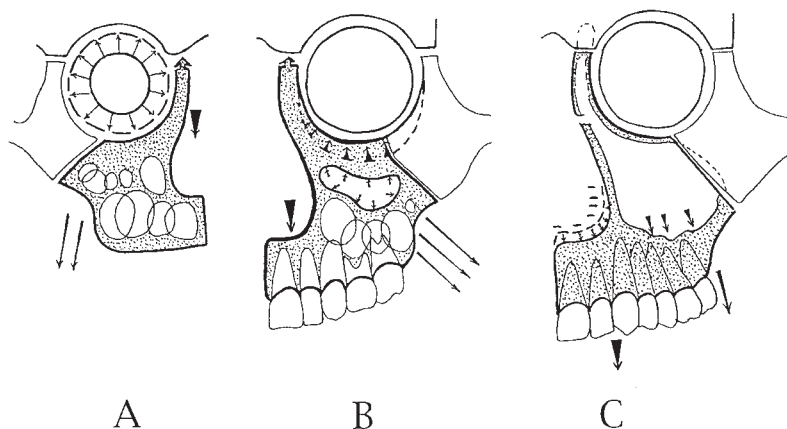


Figure 6 Schematic representation of maxillary vertical growth. (A) From 0 to 3 years of age, the downward movement of the maxilla results from the expansion of the eyeballs and muscular traction exerted on the lower part. (B) From 3 to 11 years of age, the downward movement of the maxilla is mainly due to maxillary traction. (C) After 11–12 years of age, downward movement is mainly due to the remodelling of the palatal vault and the floor of the sinuses.

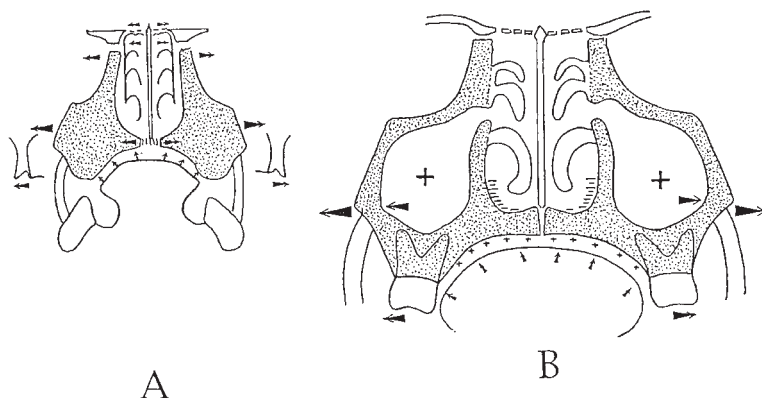


Figure 7 Schematic representation of maxillary transverse growth. (A) Before 4–5 years, the maxillae are separated 'en bloc' by the nasal capsule and pterygoid processes. (B) After 11–12 years of age, transverse development occurs outside the nasal fossae, facing the maxillary sinuses due to displacement of their lateral walls.

forward rotation, which in the very young child (when he or she is acquiring an erect posture) affect the entire maxillary block. During puberty, on the other hand (and particularly in the male), this rotation is confined to the 'anterior face'.

Vertical and transverse planes (Figures 6 and 7). It is necessary to distinguish between the 'en bloc' movements of the maxilla and 'specific' displacements of its peripheral parts in relation to its deeper parts.

In the first years of life, the maxilla moves down 'in totality' under the influence of pressure from the expanding eyes (up to the age of 3–4),

and muscular traction exerted on the lower part. Thereafter, this displacement is increased by downward movement of the palatal vault and floor of the sinuses which take on increasing importance.

Transverse plane. Up to the age of 4–5 years, the maxillary expansion is due to development of the nasal capsule and the pterygoid plates (also of cartilaginous origin). After the age of 7–10 [a time from which, according to Scott (1967), activity at the median palatal suture is greatly diminished], the maxilla develops laterally either side of the nasal fossae due to expansion of the

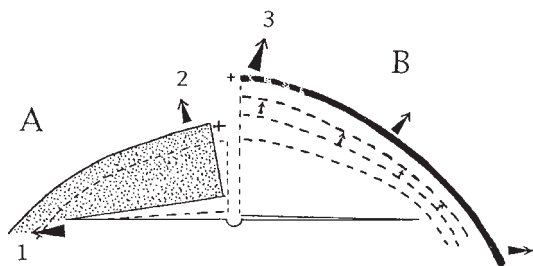


Figure 8 The premaxilla also develops by lateral (1) and rotating (2) movement of the two hemi-premaxillas and antero-lateral displacement of its external cortices (3).

maxillary sinus and displacement of their lateral walls. In cases of pathological limitation of this expansion, an underdevelopment of the maxilla occurs (Delaire, 1982). This transverse development of the maxilla and of the palatal vault essentially is the result of pressure applied by the tongue against the palatal vault and from masticatory forces transmitted to the upper teeth.

The premaxilla also develops by displacement of the two hemi-premaxillas and antero-lateral displacement of its external cortices (Figure 8), influenced by the developing tooth germs, the tongue, occlusal forces, the nasal cartilage and the naso-labial muscles.

In summary, the deeper (central) parts and the antero-lateral (peripheral) parts of the human maxilla develop differently. The deeper parts develop mainly before the age of 3–4 years under the influence of the developing cartilage of the anterior cranial base, of the intra-facial expansion, and of the eyes. Muscular action contributes to the 'en bloc' movement of these skeletal units until about 10–11 years. The anterior frontal part of the cranial base and the antero-lateral part of the maxilla together form the 'external complex', and develop for a longer period of time and in the same way. This explains why the nasion, the maxillary buttresses, the premaxilla and the zygomatic processes of the maxilla normally move at the same time. The development of the 'exo-peri-face' depends mainly on orofacial functions and, in particular, mastication and lingual pressure (Figure 9). In determining Class III malocclusions, insufficient development of the anterior face is as important as a set back of the maxilla. To correct these

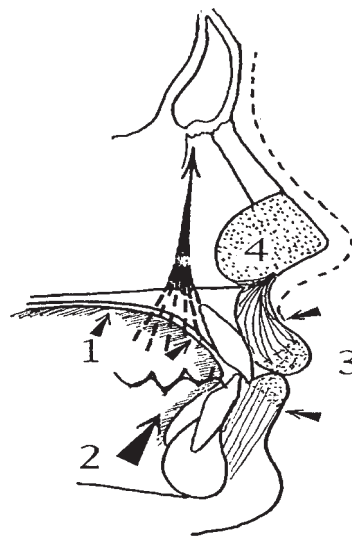


Figure 9 The main factors of the 'specific growth' of the 'anterior frontal' part of the cranial base and the antero-lateral part of the maxilla (which together form the 'external cortex'): lingual pressures against the palatal vault anterior, occlusion and mastication especially at the level of the incisors, canines and premolar areas, labial pressures balanced by the tongue pressure and the nasal cartilaginous septum.

dysmorphoses, it is necessary not only to advance the maxilla, but also to obtain the greatest development of the anterior components.

The importance of orofacial dysfunctions in establishing Class III dysmorphoses

The state of the whole cranio-facial skeleton and of its different parts is an exact reflection of cephalic posture and function (Delaire, 1980). All anomalies of posture and function of the muscles of the neck, of the deeper facial chain (soft palate, pharynx), of the lingual mass, the superficial envelope, and the masticatory muscles, can therefore have a part to play in development of skeletal anomalies. Conversely, all dento-maxillary dysmorphoses (with the exception of some rare malformation syndromes) are essentially due to postural and functional problems. To correct them requires more than normalization of skeletal form. It is necessary to correct the dysfunctions. In the absence of functional correction, it is very difficult to obtain

normal morphology and, moreover, there may be partial or complete relapse when orthopaedic treatment ceases.

These facts have been known for a long time and have been well documented. Unfortunately, they are often ignored in current orthopaedic practice. Too often, extra-oral treatment ceases whilst the dysfunctions that produce Class III persist in totality. Often even the nature of these dysfunctions is not fully assessed before treatment starts and, therefore, therapy is misdirected throughout its course! Problems with the nasal airway are often not considered. They have a major part to play in the aetiology of Class III, often more than other orofacial functions (Talmant *et al.*, 1982). It is unacceptable to see inadequate results and relapse in treatment by orthodontists who content themselves with morphological treatment.

The recommendation of the working group contained in a paper by ANDEM (Agence Nationale pour le Développement de l'évaluation médicale) regarding dento-maxillary-dysmorphoses is that 'it is inappropriate for dento-orthopaedic treatment and/or orthognathic surgery to be carried out without precise and systematic studies of orofacial functions'.

Inadequacies of conventional cephalometry in dentofacial dysmorphism syndromes and assessment of therapeutic results

Conventional telerradiographic analyses have many points which can be criticized, the most important of which are the anatomophysiological insignificance of the points N, S, A, B, Po, Ba, the lines which they unite, and the angles which are formed between them; the lack of stability of points and cephalometric lines with reference to the course of development; the meaningless norms that are applied to certain cases (Graber, 1969; Moyers and Bookstein, 1979), and the failure to take into account the cranium and the cervical spine.

The greatest drawback, however, is firstly the inability to distinguish adequately the dento-alveolus and the skeletal base and, secondly, the failure to consider the principal skeletal territories that contribute to the development of cranio-facial architectural balance. It is,

therefore, difficult to assess adequately dento-skeletal anomalies of dentofacial dysmorphoses and to study facial development. With conventional analyses, it is very difficult to understand what really happens during the course of development, with or without treatment, because, for the most part, the planes and angles that are used are not based on true morphological actions and reactions, and therefore do not allow assessments of the 'true key sites of activity during development and remodelling' (Enlow *et al.*, 1977).

Those who are particularly interested in facial development, therefore, use other systems of reference and methods of analysis (e.g. Björk, de Coster, Enlow, Fenart, McNamara, Moss).

Of all the points, lines and classic angles, I have retained only points S, N, A, B, the lines S-N, N-A, N-B, and the angles SNA, SNB, ANB. Whilst the information derived from them is limited by their imperfections, these are points that are used by many orthodontists. However, better results are obtained by craniofacial analysis and architectural superimpositions (Delaire *et al.*, 1994).

Results from a multicentre study of 172 Class III cases treated by postero-anterior extra-oral traction using an orthopaedic mask

Earlier publications and the majority of other studies concerned with this method of treating Class III related to patients in teaching hospitals. To complement this, patients treated in private practice by different orthodontists were studied to try to understand why the results of antero-posterior extra-oral traction often show great variation.

Twenty practising orthodontists submitted a total of 256 records from which patients with cleft lip and palate, Binder's syndrome, achondroplasty, and cranio-facial synostosis were excluded. Those cases where radiographs had been taken too long before treatment and after it had ceased were excluded. A total of 172 records were retained.

On each lateral cephalometric radiograph, the angles SNA, SNB and ANB were measured and architectural analyses, along with architectural superimposition, were carried out with the aid of

the Ceph-Arch and Face-Arch software program. From the large number of measurements, figures obtained and statistical results produced, the outcome can be summarized as follows:

SNA, SNB, ANB

Before treatment, there were large individual variations in SNA, SNB and ANB. SNA ranged from 68 to 90 degrees (mean 80.3), SNB from 70 to 90 degrees (mean 80.1), and ANB from -5 to +7.5 degrees (mean 0.38). There was a predominance of repositioning of the maxilla, SNA being less than 81 degrees in 52.8 per cent, between 81 and 83 degrees in 29.3 per cent, and greater than 83 degrees in 17.8 per cent of cases.

The reduced frequency in mandibular protrusion, in contrast to maxillary retrusion, was evidenced by values for SNB greater than 81 degrees in 36.78 per cent of cases, between 79 and 81 degrees in 22.41 per cent, and less than 79 degrees in 40.8 per cent.

With regard to the large variety of maxillo-mandibular anomalies, taking into account only those that occur in the sagittal plane, nine groups have been identified, which are in order of frequency: maxillary retrusion with mandibular retrusion 34.48 per cent; maxilla normally positioned with mandibular protrusion 16.09 per cent; maxillary protrusion with mandibular protrusion 13.79 per cent; maxillary retrusion with the mandible normally positioned 11.49 per cent; maxilla and mandible normally positioned 8.04 per cent; maxillary retrusion with mandibular protrusion 6.89 per cent; maxilla normally positioned with mandibular retrusion: 5.17 per cent; maxillary protrusion with mandible normally positioned 2.87 per cent; maxillary protrusion with mandibular retrusion 1.14 per cent. A Class III malocclusion can therefore exist with a mandible statistically about normal or even small (Guyer *et al.*, 1986)

Whilst the ages of the patients examined ranged from 3½ to 20 years, a very large number were children between 1 and 6 years of age. This explains the small number of cases where there was mandibular protrusion with a maxilla within the normal range (5.17 per cent), although this association is particularly common in adults, approximately 45–49 per cent. Note also the

rarity of mandibular protrusion with maxillary retrusion (6.89 per cent in this study), as opposed to 30 per cent occurring in adults in the study by Ellis and McNamara (1984). These findings confirm the frequent occurrence of mandibular prognathism in the course of development, as demonstrated in earlier work (Graber, 1969). The concept of worsening of Class III in the absence of treatment must be taken into account when analysing the results of orthopaedic therapy.

After treatment, there was an increase in the angle SNA. This was seen in 89.66 per cent of cases (on average +1.72 degrees), but with large wide variations (from -2 to 8 degrees). However, in 18 cases (10.34 per cent), there was a decrease in SNA (on average 0.80 degrees) where treatment was inadequate or badly tolerated, or where nasion moved significantly further forwards than point A. An increase in SNA depends mainly on the following.

Age of the patient: Before 6 years: an average of 2.5 degrees (maximum +8 degrees in a case having had five sessions of treatment from 5½ to 14 years); 6–12 years: an average of +1.93 degrees (maximum +7.5); 12–14 years: an average of +1.84 degrees (maximum +4.5); 14–20 years: an average of +0.37 degrees (maximum +2).

The duration of treatment: Under 5 months, the results were generally not so good (on average 1.83 degrees) as in those cases where treatment had been carried out for a minimum of 1 year or more (on average 2.4 degrees). In several cases, two or more courses of treatment were carried out and this seems to be especially true in young patients whose dysfunctions had not disappeared by the end of the first phase of treatment. It must be noted that in all the patients studied, the duration of traction in each 24 hour period did not exceed 12 hours and was often limited to 9–10 hours at night (Delaire, 1988).

The force of traction: Under 200 grams on each side (400 grams in total). The results were inadequate where the forces were 300–400 grams on each side (in total 600–800 grams).

The value of SNA and of the angle C1f1M (in

the architectural cranio-facial analysis), before traction: Statistically, where these angles were low pre-treatment, the response to therapy was better. Depending on the practitioner and the understanding of the manner in which these forces work, the major differences in the results obtained were significant. Consistent results were obtained by those familiar with the method, compared with those who used it less frequently and had less understanding of the forces required. Such practitioners often treated patients who were too old, used forces or archwires which were too light, stopped treatment too soon (when an edge-to-edge incisor occlusion had been obtained) and left persistent dysfunctions which were responsible for the malocclusion.

SNB angle: The variations were on average -0.59 , although there were some major variations between -5 and $+6$ degrees (107 negative cases average -1.65 degrees; 65 positive cases average $+1.05$ degrees). These can, in the same way, depend on different factors: mandibular rotation, backward position of the alveolar bone and/or lingual tipping of the lower incisors, mandibular angle alterations, even sometimes those of the cranial base, occipital region and even cervical spinal column.

Variations of ANB: In 93 cases this was reduced (on average by 2.34 degrees), but with major variations from -7.5 to $+4$ degrees.

Some of these findings have been published by other authors: forward movement of the maxilla by 1–2 mm (McNamara, 1987); 1.76 mm (Mermigos *et al.*, 1990); a 3 degree increase in SNA (Salagnac *et al.*, 1983) and 3.6 degrees (Cozzani, 1981); mandibular retrusion, with a decrease in SNB, on average by 1.02 degrees (Cozzani, 1981); from 0 to $+2$ degrees (Salagnac *et al.*, 1983), and without any significant change (Mermigos *et al.*, 1990), essentially due to clockwise rotation of the mandible, with however the possibility of reorientation due to the mandibular development; a reduction in ANB of -2.43 (Cozzani, 1981), to a maximum of -13 degrees (Salagnac *et al.*, 1983).

To compensate for the inability of angles SNA, SNB and ANB, and superimposition of

the points S, N, A and B, accurately to relate maxillary movements (and/or medial migration) to movement of the upper and lower dento-alveolus, to tilting of the teeth, and to lowering of the menton (clockwise mandibular rotation), we systematically use architectural analyses and superimposition (Delaire *et al.*, 1994).

Results from the cranio-facial architectural analysis and architectural superimposition

The number of different values that can be obtained from these analyses and the information gained from them will form the basis for a later publication. Those given here relate to the angles C1/f1M and f1M/f1m. These values are interesting to compare with SNA, SNB (and ANB). They show the outcome of extra-oral traction on the orientation of the maxilla with augmentation on average of the angle C1/f1M of 2.6 degrees with some quite significant variations from -2.9 to $+14.30$ degrees. In 15.69 per cent of cases, however, there was no improvement, with a diminution of this angle of 0.94 degrees. It has also been shown that there is less effect on the maxilla after the age of 13 (on average $+0.4$ degrees in 10 cases from the age of 14–20 years) contrasted with significant improvement at the end of the sixth year (on average $+3.4$ degrees in 20 children).

Also demonstrated was a frequent set back at point Me, on average -2.22 degrees (maximum -6 degrees), being almost the same in adolescence (average -2 degrees from 13 to 20 years of age). In those cases where the result was poor, this was replaced by a mandibular protrusion [$+8$ degrees in a case where mandibular development was particularly active and where treatment had been irregularly carried out, for too short a period of time (6 months) taking into account the severity of the anomaly, and where the child retained significant dysfunctions and problems with tongue posture during and at the end of treatment].

It was also noted that the variations of angles SNA, SNB, ANB were not in perfect concordance with the variation of angles C1/f1M, C1/f1m and f1m/f1M on the architectural orthognathic analysis. In fact, the variations of SNA and SNB and, therefore, those of ANB can depend on various phenomena.

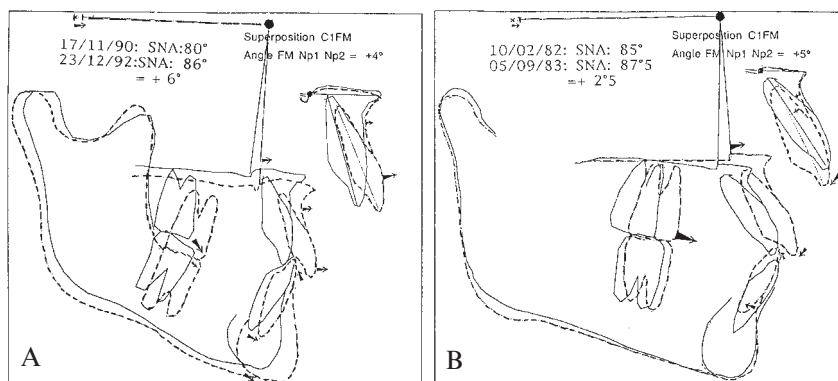


Figure 10 Variations of SNA angle depend on various phenomena. (A) A maxillary rotation (+4 degrees), together with a forward position of the labial segment alveolar bone (+1 mm), and a buccal tipping of the upper incisors (+7 degrees). At the same time there is an increase in the SNA angle (+6 degrees). (B) A backward position of the alveolar bone (-1 mm) together with a retroclination of the upper incisors (-5 degrees) reduces by half the SNA angle augmentation (+2.5 degrees) resulting in

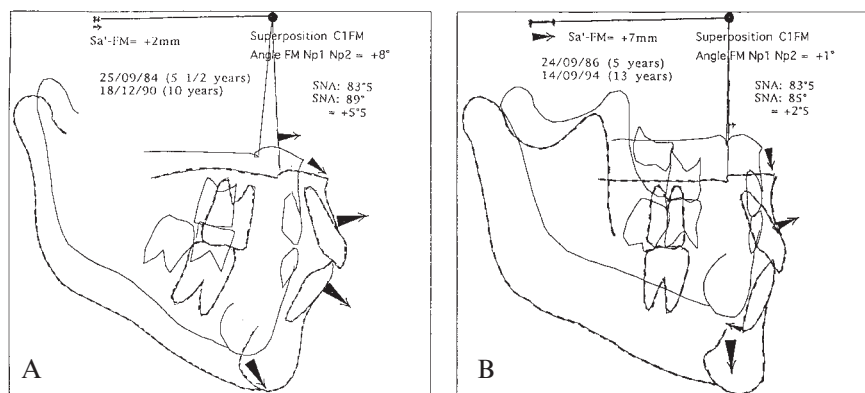


Figure 11 (A) A persistent maxillary rotation obtained by postero-anterior traction and (B) mesio-migration of FM to the base of the frontal sinus (and development of the frontal sinus) in a patient where a good anterior occlusion (and mastication) had been obtained during the course of treatment.

The following factors can change angle SNA: maxillary rotation, forward translation of fronto-maxillary articulation, alveolar bone drift of upper incisors and/or the change in their orientation. The findings show a combination of most of these factors. For instance, a maxillary rotation (+4 degrees), together with a forward position of the incisor alveolar bone (+1 mm), and a buccal tipping of the upper incisors (+7 degrees), can at the same time increase significantly the SNA angle (+6 degrees; Figure 10A). Conversely, a backward positioning and a buccal tipping of the upper incisors can reduce

by half the SNA angle augmentation (+2 degrees), resulting in a significant maxillary rotation (C1/f1M angle = +5 degrees, Figure 10B).

The state and the evolution of dysmorphism can also be studied by other measurements of the architectural analysis, but the greatest information has been obtained by tracings of the successive analyses and architectural superposition.

In this manner, we have seen that postero-anterior traction can produce, sometimes quickly (4-5 months, particularly in the deciduous or

mixed dentition), a very significant maxillary rotation (Figure 11A). On the other hand, to obtain mesio-migration of FM to the base of the frontal sinus, a much longer period of treatment is necessary (approximately 12 months; Figure 11B). Furthermore, the most important advancements were seen in cases where traction was prolonged and where a good functional occlusion was obtained during the course of treatment (the advancement produced is essentially secondary to occlusal forces rather than to the traction itself).

Posterior clockwise mandibular rotation is frequently and often the principal cause of the clinical improvement in adolescents (the architectural superimposition has confirmed the minimal effects of traction on the maxilla after the age of 14–15 years). Additionally, there may be considerable dento-alveolar variations in the incisor regions (retroclination of the alveolus, disto-version of the inferior incisors), due to pressure from the lips, especially where there is an increase in facial height.

There is often a reduction in anterior rotation of the ramus which contributes to a set back of the symphysis and the possibility for closure of the mandibular angle. There may also be a modification in the angles of the cranial base and the curve of the occipital rim in certain young patients.

Altogether, a wide range of dento-skeletal variations were seen in association with the initial malformation responsible for Class III malocclusions.

In brief, successive cephalometric analyses and architectural superimposition made it possible to confirm the tremendous variations of combinations of dento-skeletal abnormalities in Class III cases in our sample. Because of the diversity of these combinations, facemask therapy provides different results in different cases.

Note that the postero-anterior extra-oral traction produces a great diversity of modifications, which according to different cases, concerns more or less and differently, the maxilla, the mandible, the alveolar-dental arch, and/or even the cranium.

Not only do patients have their own 'individual' Class III, but they also react

'individually' to maxillary traction (examples: Figures 12–23).

The use of extra-oral traction with the orthopaedic mask in the treatment of Class III

From the above, the following recommendations and advice can be given.

(1) Orthopaedic treatment should be carried out as early as possible, either in the deciduous or at the beginning of the mixed dentition (before loss of the deciduous molars).

(2) Before treatment, it is necessary to determine exactly, using a good cephalometric analysis, the skeletal anomalies that need to be corrected and to diagnose all the dysfunctions and treat the most harmful that already exist. Where there are breathing anomalies, in order to have an effective treatment plan, an aerophonoscope should be used to quantify the problem, especially mixed respiration (sometimes difficult to assess clinically). Problems with nasal permeability may be resolved by palatal expansion (Haas, 1970; McNamara, 1987), a treatment we reserve for this problem (to prevent the post-traumatic reaction and bridge formation between the two halves of the maxilla).

(3) During treatment, the aim is, in all cases, to obtain not only maxillary advancement, but also development of the antero-lateral components, and in Class III cases with open bite, to avoid extrusion of the molars.

For this orthopaedic traction, use of a very rigid double metallic archwire attached to molar bands and whose vestibular arch is placed at a sufficient distance from the upper incisor and canine teeth (to allow spontaneous expansion in this region) is recommended. The anterior part of the vestibular arch should also have an inverted U-bend just behind the canine teeth to prevent molar extrusion (Verdon, 1974). The forces exerted on the bands should act more on the teeth than on the maxillary base and cause some extrusion. The forces exerted on a full-coverage maxillary occlusal splint result in good maxillary advancement, but impede, albeit temporarily, expansion of the anterior part.

(4) At the end of therapy, just before treatment ceases, it is necessary to reassess, cephalometrically, that the maxilla has advanced

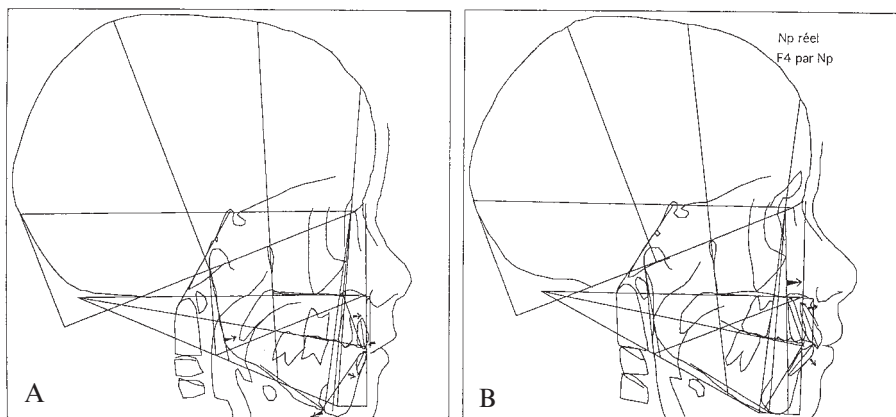


Figure 12 (MA) Long-term results of extra-oral traction by facemask therapy. (A) 25.09.84 (5 years of age). Maxilla and mandible normally positioned. The Class III malocclusion can be mostly attributed to a forward position of the inferior dento-alveolar process (+4 mm), in addition to a forward orientation of the ramus (+8 degrees) and opening of the mandibular angle (+19 degrees). (B) 18.12.90 (11 years of age), 4 years after 16 months of traction therapy. Note the amount of anterior maxillary advancement and the biprotrusion of the alveolar processes.

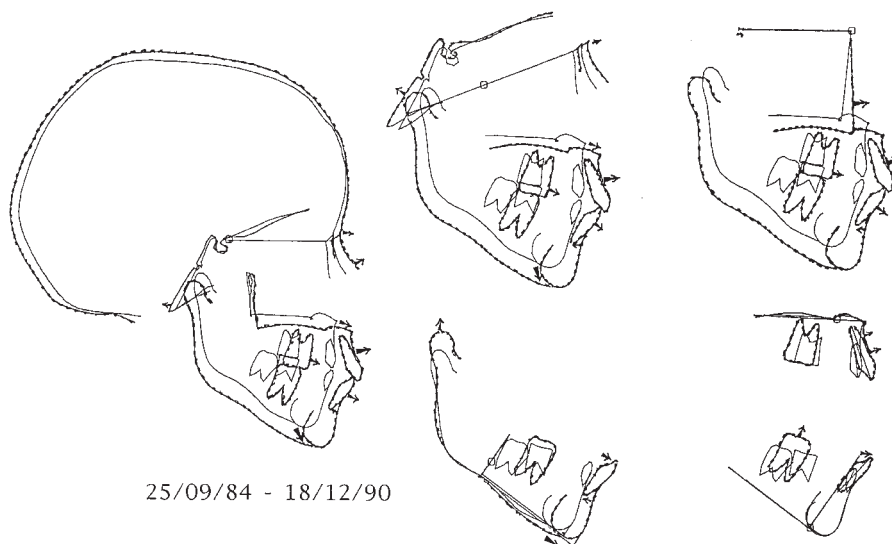


Figure 13 (MA) Architectural superimposition shows: cranial base: discrete lengthening of the anterior part (+2 mm), and an increase in the posterior angle (+4 degrees); maxilla: maxillary rotation (+8 degrees) and protrusion of the upper incisors (+2 mm, +14 degrees); mandible: buccal inclination of the inferior incisors (+19 degrees) and retroposition of the alveolar process (-2 mm).

sufficiently as a whole, and does not just affect the occlusion of the incisors and/or the molar teeth.

If there is insufficient room in the antero-lateral regions of upper dental arch, there will be inadequate space for normal eruption of the

permanent upper canine teeth. It is usual to interpret this result as a mesialization of the premolar–molar sectors under the influence of extra-oral traction. Even if this forward migration of the lateral parts of the upper maxillary dento-alveolar process has taken place, the

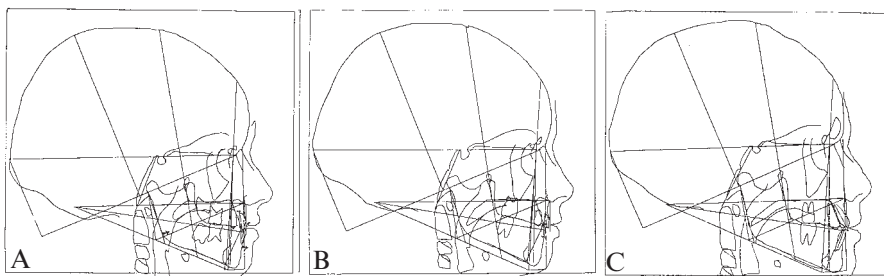


Figure 14 (TM) Long-term result of facemask therapy. (A) 24.09.86 (5 years of age). The maxilla and mandible are normally positioned. The Class III malocclusion can be mostly attributed to a forward position of the inferior dento-alveolar process (+4 mm) in addition to a forward posture of the ramus (+ 9 degrees) and opening of the mandibular angle (+14 degrees). (B) 16.01.88 (7 years of age), 14 month later, after 10 months of facemask therapy. (C) 16.04.94 (13 years of age). Note the good facial equilibrium.

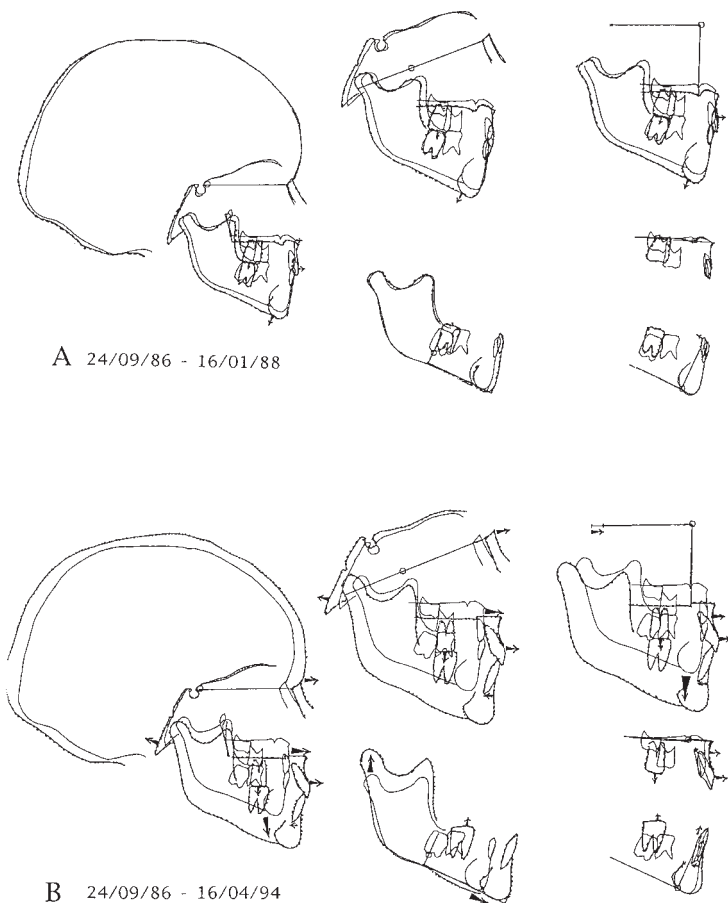


Figure 15 (TM) Architectural superimposition shows: (A) 24.09.86–16.01.88 (10 months of facemask therapy): the same maxillary orientation, a slight forward positioning of the upper incisors, a clockwise mandibular rotation and lingual tipping of the inferior incisor. (B) 24.09.86–16.04.94 (without other traction): lengthening of the anterior cranial base (+7 mm), opening of the posterior cranial angle (+6 degrees), same maxillary orientation, buccal tipping of upper incisors (+19 degrees) and backward positioning of the mandibular alveolus (–2 mm).

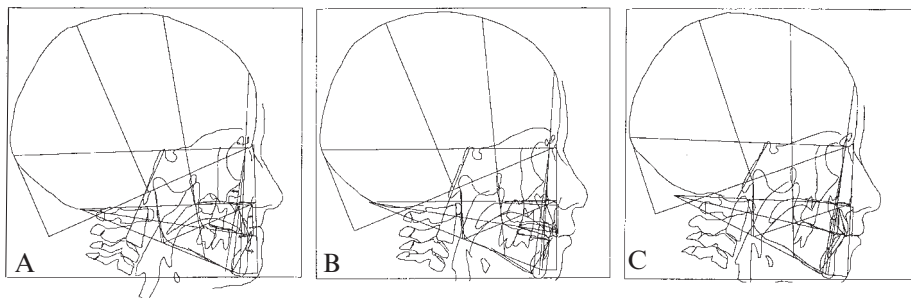


Figure 16 (JR) Architectural analyses: (A) 12.08.76 (5 years of age): Maxilla retrognathic (-6.8 degrees), mandible retrognathic (-3 degrees), backward position of the maxillary alveolus, lingual tipping of the upper incisors (-16 degrees), forward position of the mandibular alveolus ($+1$ mm). (B) 29.06.77 (6 years of age), 6 months after the beginning of facemask therapy and intermaxillary traction: one can notice the importance of the maxillary advancement ($+5.5$ degrees). (C) 23.02.80 (9 years of age), after 1 year of functional therapy (Balter's III appliance) there is a stable correction of the maxillary position and, at the same time, an improvement of the dento-alveolar areas.

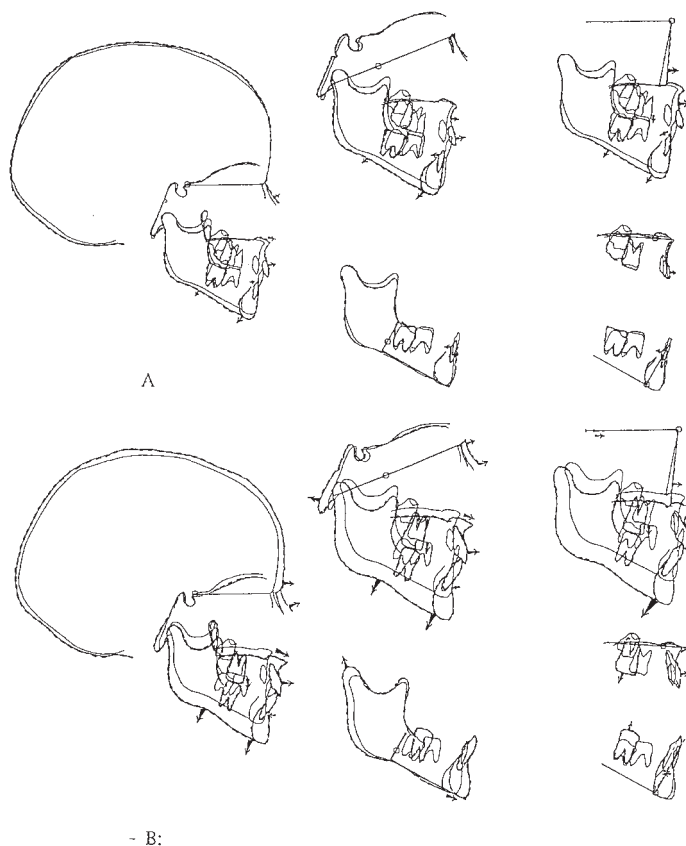


Figure 17 (JR) Architectural superimpositions. (A) 12.08.76 and 29.06.77 show the amount of maxillary rotation ($+5.5$ degrees) associated with mandibular clockwise rotation, buccal tipping of upper incisor ($+7$ degrees) and lingual tipping of inferior incisor (-5 degrees). (B) 12.08.76–23.02.80 (3 years and 6 months after the end of traction) confirm the stability of the maxillary position and the improvement of dento-alveolar areas; furthermore lengthening of the anterior cranial base can be seen ($+4$ mm).

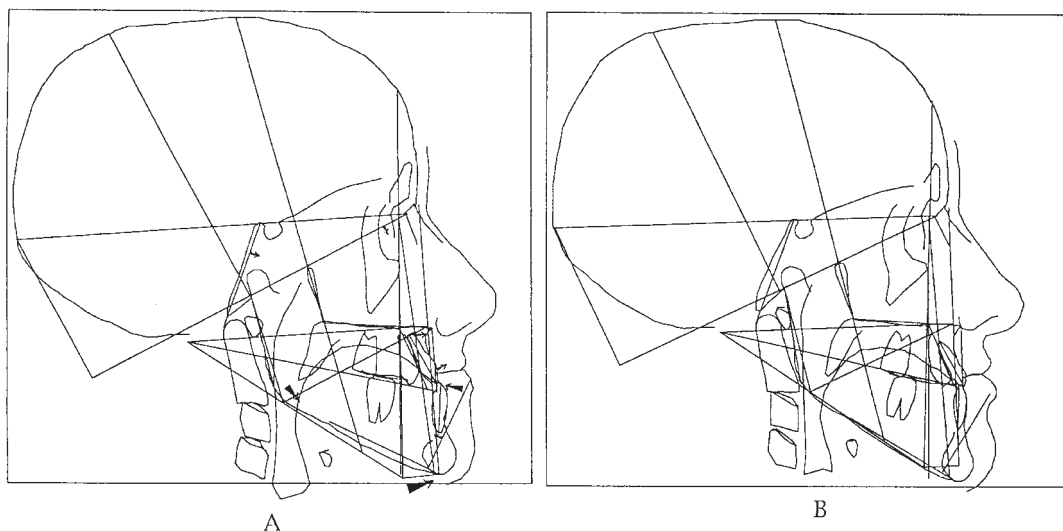


Figure 18 (TD) (A) 25.01.91, 15 years: Cranial predisposition to Class III (anterior angle +1 degree, posterior angle -2 degrees). Maxilla normally positioned, prognathic mandible (+11 mm). Forward position of maxillary alveolus (+2 mm), buccal tipping of upper incisors (+4 degrees). Backward position of mandibular alveolus (-2 mm), lingual tipping of inferior incisors (-24 degrees), opening of the mandibular angle. Facemask therapy from 25.01.91 (15 years) to 10.06.92. (B) 25.06.92, 16½ years of age after 17 months of treatment.

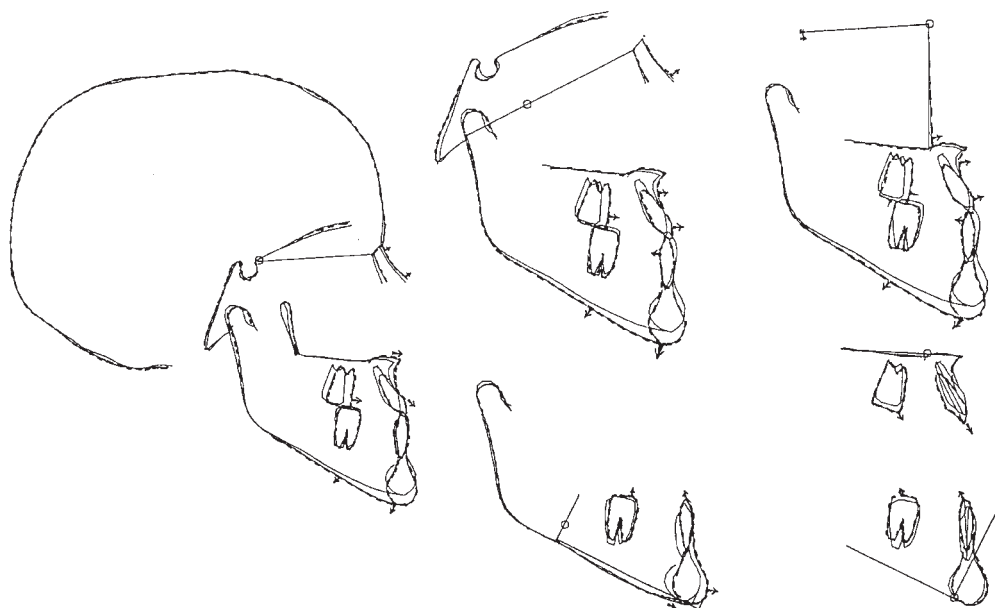


Figure 19 (TD) Superimposition shows that the progress obtained results in a discrete advancement of FM (+1 mm) and anterior rotation of the maxilla (+1 degree), associated with a clockwise mandibular rotation, an extrusion of both upper and lower incisors, a backward position (-2 mm) with retroclination of mandibular incisors (-6 degrees), and opening of the mandibular angle (+2 degrees).

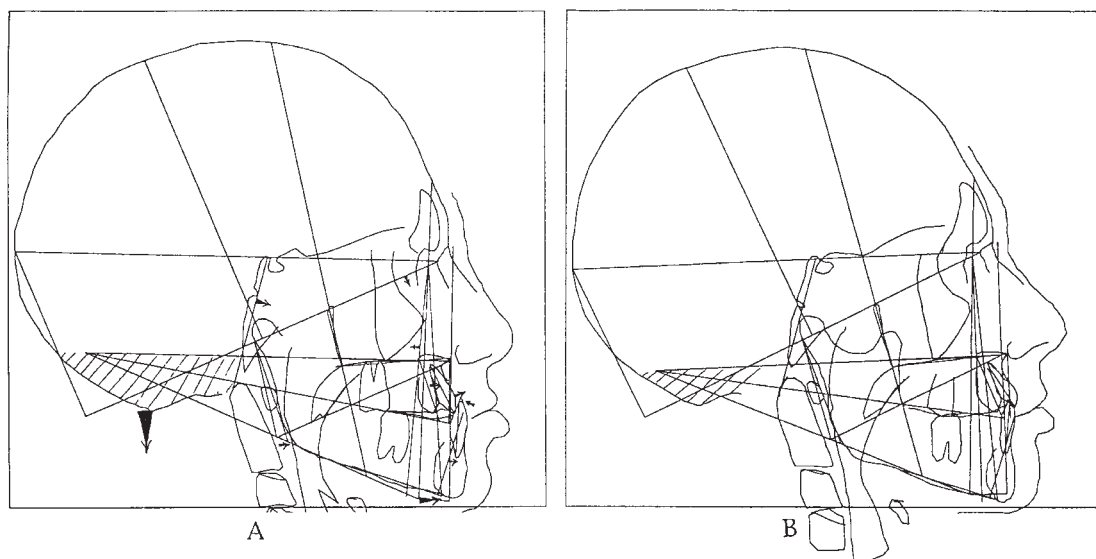


Figure 20 (JT) (A) 27.10.89, 11 years of age. Cranial predisposition to Class III (anterior angle +2 degrees, sphenoidal angle -12 degrees, counterclockwise occipito-temporal rotation). Maxilla retrognathic (-4.2 degrees), mandible prognathic (+5.9 degrees, +10 mm), forward posture of the ramus (+6 degrees), forward position of maxillary alveolus (+2 mm), buccal tipping of upper incisors (+7 degrees), forward position of mandibular alveolus (+3 mm), lingual tipping of mandibular incisors (-15 degrees). (B) 30.09.92, 14 years of age [facemask therapy 17.01.90-11.12.91 = 11 months + multiband with inter-maxillary traction (11.12.91-30.06.92)].

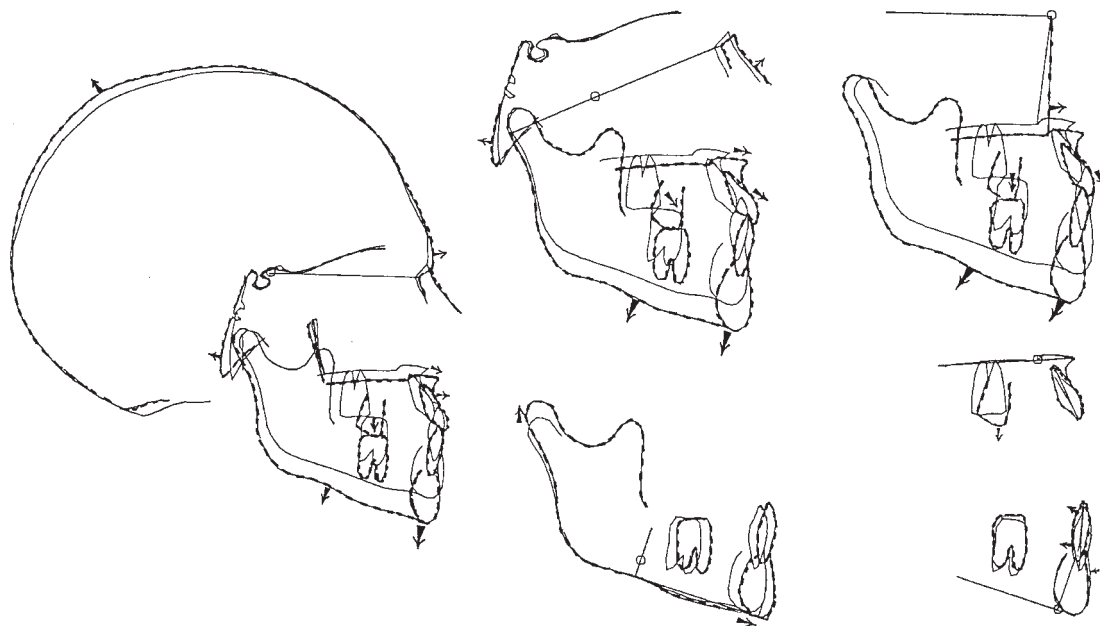


Figure 21 (JT) Architectural superimposition shows that the progress obtained results in a decrease (but no disparition) of the occipito-temporal rotation associated with an opening of the sphenoidal angle (+4 degrees) and reduction of the anterior angle (-1 degree), forward maxillary rotation (+7.3 degrees), clockwise mandibular rotation, a slight posterior position of the anterior lower alveolar bone (-2 mm), associated with a straightening of the anterior part of the mandibular symphysis. Prognathic mandible persists (+7.1 degrees, +12.3 mm)

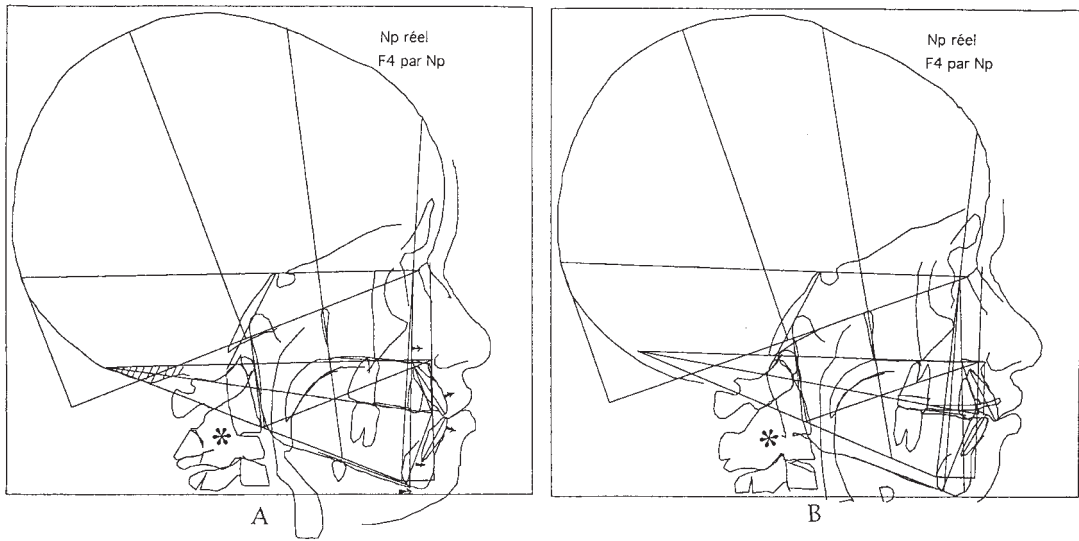


Figure 22 (IR) (A) 10.02.82 (10 years of age). Maxilla prognathic (+2.4 degrees), mandible prognathic (+ 2.4 degrees, + 4 mm), lower dento-alveolar protrusion (+3 mm), buccal tipping of the upper (+11 degrees) and inferior incisor (+9 degrees). A synostosis between second and third cervical vertebrae results in the forward position of the tongue, representing an aetiological factor of Class III. (B) 06.09.83 (11 years of age), 18 months after 18 months of facemask therapy.

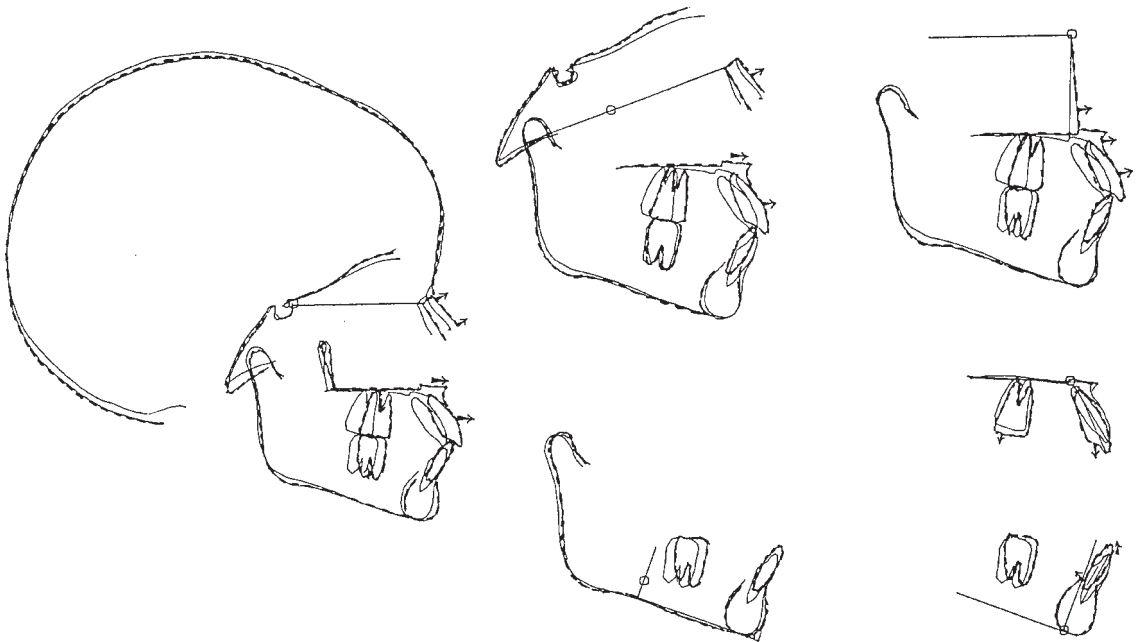


Figure 23 (IR) Architectural superimposition shows that the progress obtained results essentially in a forward maxillary rotation (7.7 degrees = +5.3 degrees).

principal result is hypodevelopment of the antero-lateral parts of the maxilla, particularly of the premaxilla. This commences in the deciduous dentition with inversion of the anterior occlusion. In this situation, there is a contraindication to extraction of the first upper premolar teeth which would exaggerate this hypodevelopment of the anterior part of the maxilla even further. A base for the canines must be found by other means—by anterior palatal expansion and/or extra-oral traction exerted only on the upper incisor block (Delaire, 1990). After rearrangement of the incisors and canines, the palatal arch needs to be maintained in this shape for a sufficient period of time to allow for normalization of masticatory functions in the anterior region, as well as posture and movement of the tip of the tongue, and posture and function of the lips.

In certain types of Class III cases, where the upper lateral incisors are absent, space closure between the central incisors and the canines should be avoided, maintaining it either with a prosthesis or implants.

In many cases in this study, the results have been inadequate because these principles have not been adhered to.

(5) After treatment has finished, it is vital to maintain the maxillary advancement that has been produced by the traction and, additionally, to obtain good development of the antero-lateral parts. For this to occur, it is essential that muscle posture and orofacial functions are rendered 'normal'. The use of a functional appliance such as the bionator of Balters or a Fränkel appliance is recommended. The use of a multibanded appliance, when the functions have not been normalized, results in some degree of failure and relapse.

(6) In certain syndromes, extra-oral traction on the maxilla will act in a different way, for example, where sutural ossification is very delayed (with the maxilla still moving during adolescence, such as in cleidocranial dysostosis). In one case observed in this study (but not included in the statistics), treatment bilaterally for 11 months with a force of 450 g resulted in a significant advancement of the maxilla, essentially by rotation, with an SNA of +4

degrees, C1/1M +6, despite the patient approaching 15 years of age. Conversely, when there has been premature synostosis (as in Crouzon's syndrome), this treatment will have no effect on the maxilla.

It is not illogical to think that all normal subjects do not have exactly the same potential for sutural response (it has been observed in animals), nor the same capacity for mandibular development. This may explain certain different responses to the same forces of orthopaedic maxillary treatment.

(7) In certain circumstances, it may be necessary for surgical treatment to be undertaken, before, during or after treatment. In particular, the removal of the tonsils and adenoids if they are responsible for nasal respiration and advancement of the mandibulo-lingual complex; a reduction glossoplasty (glossectomy) in cases where there is true macroglossia; a functional genioplasty, after eruption of the lower permanent canines, if there is excessive height of the symphysis causing incompetent lips with contraction of the labio-mental muscles; in Binder's syndrome (Rune *et al.*, 1982), where it is necessary to carry out a restoration of the naso-labial musculature, reinserting them into the nasal cartilaginous septum and the region of the anterior nasal spine which will have been recreated with a bone graft (Delaire, 1989).

(8) The treatment of Class III in cleft lip and palate is particularly difficult, with variable results (Verdon, 1974; Delaire *et al.*, 1978; Friede and Lennartsson, 1981; Rygh and Tindlund, 1982). There are a number of anatomical and functional reasons for this.

(8.1) *Where primary surgery has been inadequate:* poor reconstruction of the naso-labial muscles, acting against the anterior part of the maxilla with poor development of the premaxilla and the anterior parts of the lateral maxillary fragments (Delaire, 1989); scarring of the vomero-palatine junction preventing maxillary advancement and reduction in nasal permeability of the nasal fossae which results in oral breathing with hypertrophy of the adenoids and forward positioning of the base of the tongue (which is further accentuated by flattening and tightness of the palatal vault as

well as immobility and shortness of the soft palate) (Delaire, 1989).

(8.2) *The absence of secondary surgery or inadequate techniques*: the absence of improvement of the nasal airway, the nasal fossae, the cavum, persistence of the enlarged adenoids, insufficient muscular rehabilitation of the soft palate and the lip (Delaire, 1989), etc., or where insufficient surgical procedures have been carried out. This point is very important. Identical surgical procedures can apparently give quite different results depending on the techniques used. For example, after secondary surgery for the soft palate, the results may be very different depending on the type of velo-pharyngoplasty carried out, and whether in so doing the dimension and function of the soft palate have an effect on nasal breathing. Quite often, a simple pharyngoplasty results in oral breathing which secondarily exaggerates the Class III (Subtelny and Pineda Nieto, 1978).

(8.3) The difference in results can also be due to the type of orthodontic and orthopaedic appliance used (a rigid archwire and multibands, aiming to ankylose the deciduous canines, with or without palatal expansion). Additionally, the strength, direction and duration of treatment are important.

At the end of development, the final state may rely more on surgery (primary and secondary) and on the functional abilities of the patient after these operations, than on orthopaedic treatment itself.

Conclusions

Normal development of the maxilla results not only from movements of its constituent skeletal units and bony apposition-resorption superficially, but also from the specific development of the antero-lateral regions.

In Class III cases, correction of the dysmorphism requires not only that the maxilla is in a correct position (in relation to the mandible) and that the correct occlusion is achieved, but also that there is development of the exo-peri-premaxilla which requires normalization of muscular posture (labio-mental, lingual, velo-pharyngeal) and of orofacial functions

(nasal ventilation, swallowing, mastication). Postero-anterior traction using an orthopaedic mask can only accomplish part of the treatment of Class III. Whilst improving the position and orientation of the maxilla enables improved facial development, this must always be complemented by other therapy aimed at correcting the underdevelopment of the antero-lateral regions. The treatment takes time. Rapid skeletal movements are spectacular, but too brutal, and it is preferable that treatment is more physiological, slower, longer lasting, and associated with other functional appliances. Facemask therapy is not only simple sagittal distraction, but is truly a method for the treatment of Class III malocclusions which is well understood and achieves excellent results.

Considering the great diversity of anatomical forms of Class III, it is not surprising that extra-oral postero-anterior traction gives widely varying results. The quality, however, depends principally on the method used.

Orthodontists must not hesitate to call for the assistance of a surgeon when functional treatment is insufficient. In these cases, and particularly in clefts, the results depend more on surgical procedures, both primary and secondary, than on dentofacial orthopaedics.

Address for correspondence

Professor J. Delaire
8 rue Horace Vernet
44100 Nantes
France

Acknowledgements

I am grateful to Mme H. Hejazi, T. MarKus and A. Decker for their assistance with the translation, and to Mme E. Di Malta, M. Vesse and J. Eoche-Duval for their documentation (Figures 12–23).

References

- Augier M 1931 Squelette céphalique. In Poirier P, Charpy A (eds) *Traité d'anatomie humaine*. Volume 1. Masson & Co. Paris
- Baumrind S, Korn E L, Isaacson R J, West E E, Molthen R 1983 Quantitative analysis of the orthodontic and

- orthopedic effects of maxillary traction. *American Journal of Orthodontics* 84: 384–398
- Björk A, Skieller V 1977 Growth of the maxilla in three dimensions as revealed radiographically by the implant method. *British Journal of Orthodontics* 4: 53–64
- Brown W A, Molleson T I, Chinn S 1984 Enlargement of the frontal sinus. *Annals of Human Biology* 11: 221–226
- Cozzani G 1981 Extraoral traction and Class III treatment. *American Journal of Orthodontics* 80: 638–650
- de Coster L 1952 La croissance de la face et des dents. *Orthodontie Française* 23: 21–124
- Delaire J 1971 La croissance maxillaire: déductions thérapeutiques. *Transactions of the European Orthodontic Society*, pp. 81–102
- Delaire J 1976 Le syndrome prognathique mandibulaire. *Orthodontie Française* 47: 203–219
- Delaire J 1980 Essai d'interprétation des principaux mécanismes liant la statique à la morphogénèse céphalique. *Déductions cliniques. Actualités Odonto-Stomatologiques* 130: 189–220
- Delaire J 1982 Les dysmorphoses faciales par trouble de la croissance du sinus maxillaire (Quelques exemples cliniques). *Orthodontie Française* 53: 417–430
- Delaire J 1988 L'emploi physiologique des tractions extra-orales postéro-antérieures sur masque orthopédique dans le traitement des classes III. *Orthodontie Française* 59: 577–589
- Delaire J 1989 La réhabilitation fonctionnelle chirurgicale et orthopédique des fentes labio-maxillo-palatines congénitales. Volumes 1 and 2. *Associazione Labio-Palato-Schisi. Tipografia. Lompomo. Como. Italy*
- Delaire J 1990 Delaire-Maske mit starken extraoralen Kräften in posterior-anteriorer Richtung. In: Delaire J, Komposch G (eds) *Orthopädische Beeinflussung des Oberkieferkomplexes. Keferorthopädie I Praxis der Zahnheilkunde* 11. Urban-Schwartzberg, München, pp. 251–288
- Delaire J, Précious D 1987 Interaction of the development of the nasal septum, the nasal pyramid and the face. *International Journal of Pediatric Otorhino-laryngology* 12: 311–326
- Delaire J, Verdon P, Flour J 1978 Möglichkeiten und Grenzen extraoraler Kräfte in postero-anteriorer Richtung unter Verwendung der orthopädischen Maske. *Fortschritte der Kieferorthopädie* 39: 27–45
- Delaire J *et al.* 1994 Diagnostic des dysmorphoses dento-maxillo-faciales. Apport de l'analyse architecturale informatisée. *Actualités Odonto-Stomatologiques* 187: 477–511
- Delattre A, Fenart R 1960 L'hominisation du crâne. *Centre National de la Recherche Scientifique, Paris*
- Ellis E, McNamara J A Jr 1984 Components of adult Class III malocclusion. *Journal of Oral and Maxillofacial Surgery* 42: 295–305
- Enlow D H (ed) 1968 *The human face*. Hoeber. New York
- Enlow D H, Bang S 1965 Growth and remodeling of the human maxilla. *American Journal of Orthodontics* 51: 446–464
- Enlow D H, Harvold E P, Latham R A, Moffett B C, Christiansen R L, Hausch H G 1977 Research on control of craniofacial morphogenesis: an NIDR State-of-the-Art Workshop. *American Journal of Orthodontics* 71: 509–530
- Fenart R 1985 Les prognathismes en orientation vestibulaire. *Bulletin et Mémoires de la Société d'Anthropologie de Paris*, tome 2, série XIV 1: 39–52
- Ford E H R 1958 Growth of the human cranial base. *American Journal of Orthodontics* 44: 498–506
- Friede H, Lennartsson B 1981 Forward traction of the maxilla in cleft lip and palate patients. *European Journal of Orthodontics* 3: 21–39
- Graber T M (ed) 1969 *Current orthodontic concepts and techniques*. W B Saunders Co. Philadelphia
- Guyer E C, Ellis III E E, McNamara J A Jr., Behrents R G 1986 Components of Class III malocclusion in juveniles and adolescents. *Angle Orthodontist* 56: 7–30
- Haas A J 1970 Palatal expansion: just the beginning of dento-facial orthopedics. *American Journal of Orthodontics* 57: 219–255
- Irie M, Nakamura S 1975 Orthopedic approach to severe skeletal Class III malocclusion. *American Journal of Orthodontics* 67: 377–392
- Jackson G W, Kokich V G, Shapiro P A 1979 Experimental and postexperimental response to anteriorly directed extra-oral forces in young *Macaca nemestrina*. *American Journal of Orthodontics* 75: 318–333
- Klaauw C J van der 1946 Cerebral skull and facial skull. *Archiv Neerland Zoology* 7: 16–39
- Lebourg L, Seydel S 1932 Nature, évolution et rôle des articulations de la face. Leur importance physiopathologique. *Revue de Stomatologie* 34: 193–210
- McNamara J A Jr 1987 An orthopedic approach to the treatment of Class III malocclusion in young patients. *Journal of Clinical Orthodontics* 21: 598–608
- Maresh M M (1940) Paranasal sinuses from birth to adolescence. *American Journal of Disorders of Childhood*. 60: 55–78
- Mermigos J, Full C A, Andreasen G 1990 Protraction of the maxillofacial complex. *American Journal of Orthodontics and Dentofacial Orthopedics* 98: 47–55
- Moss M, Young R W 1960 A functional approach to craniology. *American Journal of Physical Anthropology* 18: 281–291
- Moss M L, Greenberg S N 1967 Functional cranial analysis of the human maxillary bone. I: Basal bone. *Angle Orthodontist* 37: 151–164
- Moyers R E, Bookstein F L 1979 The inappropriateness of conventional cephalometrics. *American Journal of Orthodontics* 75: 599–617
- Rune B, Sarnäs K-V, Selvik G, Jacobsson S 1982 Postero0 anterior traction in maxillonasal dysplasia-Binder Syndrome, a roentgen stereometric study with the aid of metallic implants. *American Journal of Orthodontics* 81: 65–70
- Rygh P, Tindlund R 1982 Orthopedic expansion and protraction of the maxilla in cleft palate patient. A new treatment rationale. *Cleft Palate Journal* 19: 104–112
- Salagnac J M, Verdon P, Delaire J 1983 Etudes téléradiographiques des effets des tractions postéro-

- antérieures sur masque orthodontique dans le traitement des classes III (séquelles des fentes labio-maxillaires exclues). Bilan des résultats obtenus dans 60 cas. Volume du Vème congrès de Stomatologie et de Chirurgie Maxillo-Faciale. Masson, Paris, pp. 135–140
- Sarnäs K V, Rune B 1987 Extraoral traction to the maxilla with face mask: a follow-up of 17 consecutively treated patients with and without cleft lip and palate. *Cleft Palate Journal* 24: 95–103
- Scott J H 1967 Dentofacial development and growth. Vol. 6. Pergamon Press. Oxford
- Solow B, Tallgren A 1971 Postural changes in cranio-facial relationships. *Acta Odontologica Scandinavica* 7: 1247–1257
- Subtelny J D, Pineda Nieto R 1978 A longitudinal study of maxillary growth following pharyngeal-flap surgery. *Cleft Palate Journal* 15: 118–131
- Talmant J, Rouvre M, Thibult J L, Turpin P. 1982 Contribution à l'étude des rapports de la ventilation avec la morphogénèse cranio-faciale. Dédutions thérapeutiques concernant l'ODF Rapport au 55ème congrès de la SFODF *Orthodontie Française* 53: 7–181
- Topinard P 1891 *L'homme dans la nature*. F Alcan. Paris.
- Vego L 1976 Early orthopedic treatment for Class III skeletal patterns. *American Journal of Orthodontics* 70: 59–69
- Verdon P 1974 Nouvelles orientations des traitements des sequelles maxillo-dentaires des fentes labio-maxillaires totales avec division palatine (question mise en discussion). *Orthodontie Française* 45: 11–49
- Weidenreich F 1924 Über die pneumatischen Nebenräume des Kopfes. Ein Beitrag zur Kenntnis des Bauprinzips der Knochen, des Schädels und des Körpers. *Anatomisch Entgesch* 72: 55–93