

Uncovering labially impacted teeth: apically positioned flap and closed-eruption techniques

Michael E. Vermette, DMD, MSD; Vincent G. Kokich, DDS, MSD;
David B. Kennedy, BDS, MSD

Labial tooth impaction occurs in 1% to 2% of orthodontic patients and is often difficult to manage.^{1,2} The most common methods of uncovering labial impactions have been the excisional gingivectomy and the apically positioned flap techniques.³⁻⁶ Only a few surgeons have used the closed-eruption technique.⁷⁻¹³ The esthetic and functional outcomes of these procedures, such as effects on gingival height, clinical crown length, width of attached gingiva, gingival scarring, relapse potential, and attachment levels need to be critically assessed in order to identify the optimal

method of uncovering labial impactions.

Vanarsdall and Corn³ evaluated more than 75 labially impacted teeth which had been uncovered using a split-thickness apically positioned flap. The authors found no marginal bone loss or gingival recession after orthodontic treatment. They stressed the need to provide attached gingiva in order to prevent the muscles of the face from detaching the marginal periodontal tissue from the tooth, causing marginal bone loss and gingival recession.

The closed-eruption technique is believed by some to be the best method of uncovering la-

Abstract

The purpose of this study was to examine the esthetic and periodontal differences between two methods of uncovering labially impacted maxillary anterior teeth: the apically positioned flap and closed-eruption techniques. The sample consisted of 30 patients who were recalled a minimum of three months after orthodontic treatment of a unilateral labially impacted maxillary anterior tooth. Eighteen of the patients had undergone an apically positioned flap (APF) procedure, and the remaining twelve had undergone the closed-eruption (CE) technique. In the CE group, clinical examination showed less width of attached gingiva on the distal surface and increased probing bone level on the facial surface of the uncovered teeth relative to their contralateral controls. Uncovered teeth in the APF group showed more apical gingival margins on the mesial and facial surfaces; greater crown length on the midfacial surface; increased probing attachment level on the facial surface; increased width of attached gingiva on the facial surface; increased probing bone level on mesial, facial, and distal surfaces; and gingival scarring. Radiographic examination showed shorter roots on the uncovered teeth in both groups. Photographic examination revealed vertical relapse of the uncovered teeth in the APF group. We conclude that labially impacted maxillary anterior teeth uncovered with an apically positioned flap technique have more unesthetic sequelae than those uncovered with a closed-eruption technique.

Key Words

Orthodontics • Impacted teeth • Surgical exposure • Esthetics • Periodontium

Submitted: May 1994

Revised and accepted: August 1994

Angle Orthod 1995;65(1):23-34.

Figure 1

An adolescent patient with a severely impacted maxillary central incisor uncovered with an apically positioned flap.

A: Pretreatment view, prior to opening space for the impacted tooth.
B: The central incisor was surgically uncovered.

C: Two weeks after the uncovering, orthodontic traction was applied to erupt the tooth.

D: The central incisor was positioned properly within the dental arch.

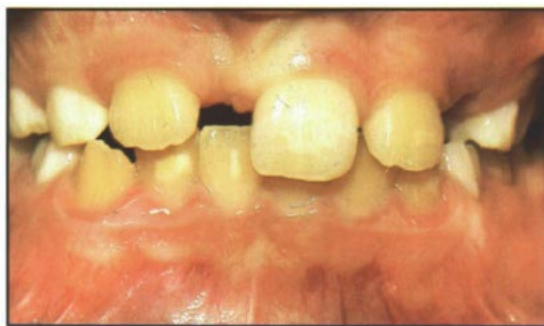

Figure 1A

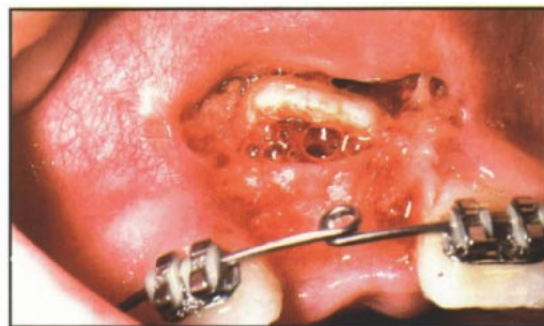


Figure 1B

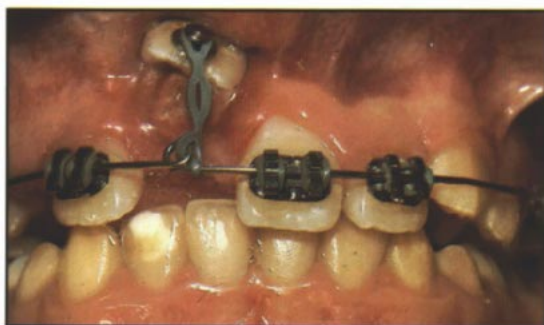


Figure 1C

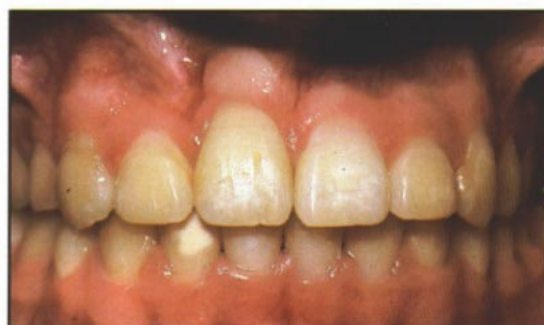

Figure 1D

Table I
Description of the patient samples

	Mean	Range
I. CE (N = 12)		
Age at start of treatment:	12 yr 1 mo	7 yr 6 mo - 15 yr 9 mo
Treatment duration:	28.5 mo	14 mo - 51 mo
Recall period:	38.5 mo	3 mo - 86 mo
Age at recall:	17 yr 5 mo	10 yr 1 mo - 23 yr 11mo
II. APF (N = 18)		
Age at start of treatment:	13 yr 3 mo	8 yr 3 mo - 21 yr 1mo
Treatment duration:	28.2 mo	18 mo - 59 mo
Recall period:	26.8 mo	3 mo - 98 mo
Age at recall:	17 yr 10 mo	11 yr 4 mo - 25 yr 6 mo

bially impacted teeth, especially if the tooth is located high above the mucogingival junction or deep in the alveolus where an apically positioned flap may be difficult or impossible to use successfully.⁸⁻¹³ With the CE technique, the crown of the tooth is exposed, an attachment is fixed to it, and the flap is sutured back over the crown. A wire or chain extends from the attachment through the coronal part of the flap.^{7,8} Some clinicians believe that the closed-eruption method replicates natural tooth eruption and therefore produces the best esthetic and periodontal results.⁹

The purpose of this study was to examine the esthetic and periodontal differences between the apically positioned flap and closed-eruption techniques for uncovering labially impacted maxillary anterior teeth.

Materials and methods

Sample

The sample consisted of 30 patients who were recalled a minimum of 3 months after orthodontic treatment of a unilateral labially impacted maxillary anterior tooth. The sample was divided into two groups based on the method of uncovering of the impacted tooth: 18 of the patients had undergone an apically positioned flap (APF) procedure, and the remaining 12 had undergone the closed-eruption (CE) technique. The age at the start of treatment, treatment duration, recall period, and age at the time of recall were similar for both

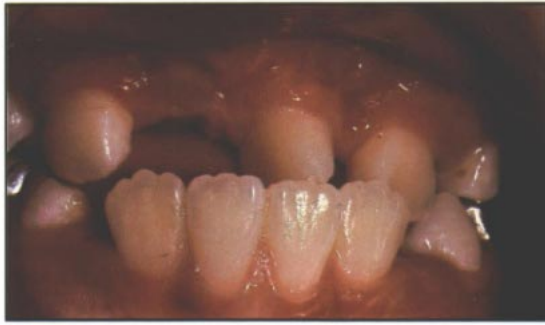

Figure 2A

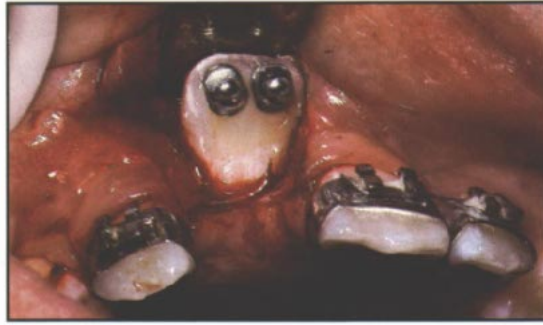


Figure 2B

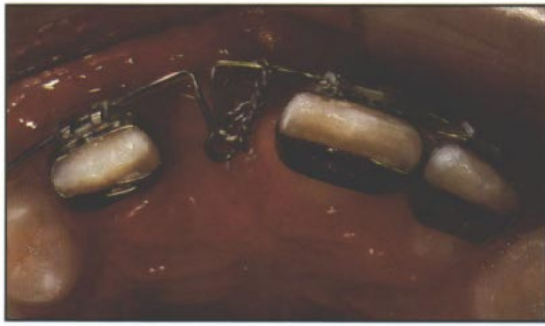

Figure 2C

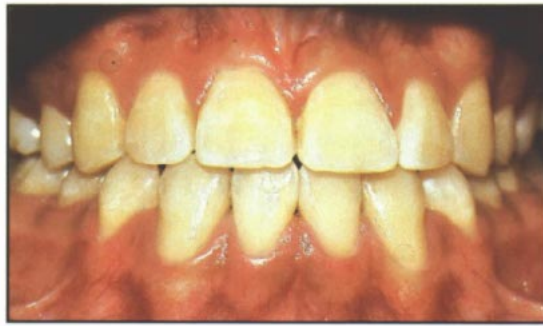

Figure 2D

Figure 2

An adolescent patient with a severely impacted maxillary central incisor uncovered with a closed-eruption technique.

A: Pretreatment view, prior to opening space for the impacted tooth.
B: The central incisor was surgically uncovered.

C: One week after uncovering, orthodontic traction was applied to erupt the tooth.

D: The central incisor was aligned properly within the dental arch.

groups (Table I). In 28 patients, an attachment was bonded to the impacted tooth at the time of the surgical exposure; pins were placed in two teeth, both in the CE group. Light, continuous orthodontic forces were applied about 2 weeks after the uncovering in all cases.

Surgical techniques

The apically positioned flap is a split-thickness pedicle reflected from the edentulous area³ (lateral to the area in the case of an impaction that is positioned lateral to the edentulous site⁸) saving as much gingiva as possible. In this sample the incisions extended vertically into the vestibule, and a split-thickness flap was reflected. Bone covering the enamel was removed with a curette or a No. 6 surgical round bur. Two-thirds of the crown was exposed, and the connective tissue follicle was curetted from the periphery of the exposed portion of the crown. The flap was sutured to the periosteum, leaving one-half to two-thirds of the crown uncovered. A surgical dressing was placed on the enamel to prevent overgrowth of adjacent tissue. The dressing was removed 1 week postoperatively, and the patient was instructed to keep the coronal surface clean. The patient saw the orthodontist 2 weeks after the surgery and an attachment was placed on the uncovered tooth (Figure 1).

The closed-eruption technique involved elevating a flap, placing an attachment on the impacted tooth, and returning the flap to its

original location.^{7,8} If the tooth was impacted in the midalveolar area, a crestal incision was made, and buccal and palatal flaps were reflected from the edentulous ridge. Curettes and surgical round burs were used to find the tip of the impacted tooth, and enough bone was removed from the incisal portion to place an attachment. If the tooth was displaced near the nasal spine, a pedicle flap was reflected. An 0.010-inch ligature wire or gold chain was attached from a pin or mesh pad to the archwire. The flaps were returned to their original position for complete closure. The wire or chain passed under the flap and exited at the midcrestal incision. The orthodontist typically activated force within 1 week, creating a normal direction of tooth eruption (Figure 2).

Clinical evaluation

The test tooth (previously impacted) and its contralateral control tooth were examined by the senior author. Measurements were made at the mesiobuccal, midbuccal, and distobuccal surfaces. Oral hygiene and gingival inflammation were evaluated using the Visible Plaque Index and Gingival Bleeding Index.¹⁴ Probing pocket depth was measured to the nearest 0.1 mm using a standardized force probe (0.25 Newtons, Florida Probe Co., Gainesville, Fla). The distance from the gingival margin to the cemento-enamel junction (CEJ) was measured to the nearest millimeter using a Michigan "O" periodontal probe with Williams' markings. A negative recording indicated that the gingival

Figure 3
Classification and examples of different severities of impaction.

A: The classification of impaction is determined by the distance, *x*, measured from the pretreatment panoramic radiograph.

B: A mild impaction, where the distance, *x*, is less than 12 mm.

C: A moderate impaction, where the distance, *x*, is 12 to 15 mm.

D: A severe impaction, where the distance, *x*, is greater than 15 mm.

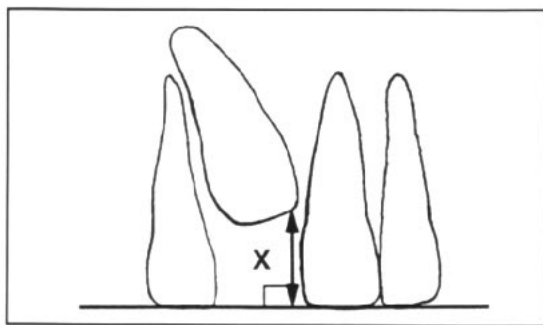


Figure 3A

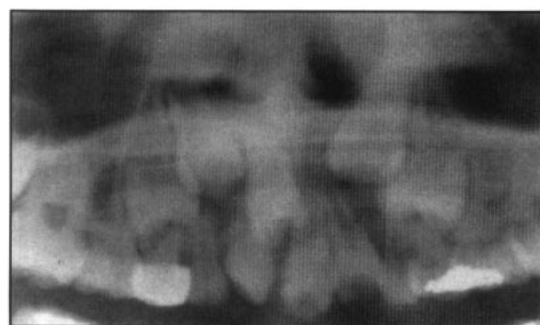


Figure 3B

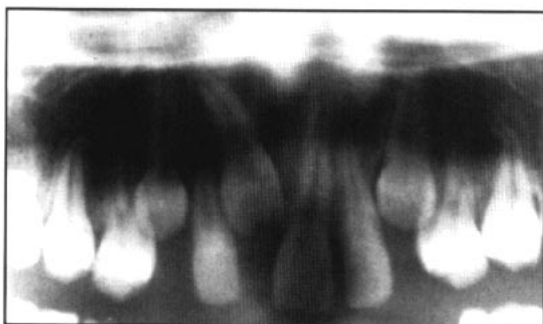


Figure 3C

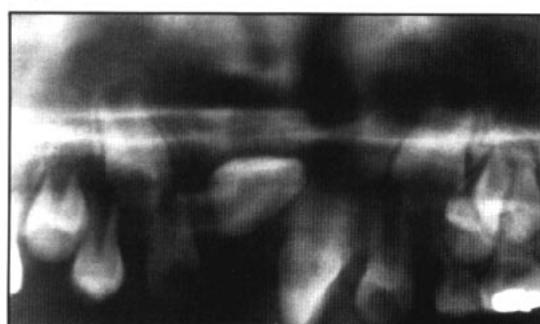


Figure 3D

margin was located apical to the CEJ. The width of gingiva was the distance from the gingival margin to the mucogingival junction measured to the nearest 0.1 mm using electronic calipers. Schiller's IKI solution¹⁵ was used to identify the mucogingival junction. The distance from the gingival margin to the bone was measured to the nearest millimeter using a Michigan "O" probe.¹⁶ The gingiva was anesthetized topically with 20% benzocaine applied with a cotton swab 30 seconds prior to measuring.

Three of the variables were calculated as differences between measures. Probing attachment level was calculated by subtracting the distance CEJ to gingival margin from the probing pocket depth. The width of attached gingiva was calculated by subtracting the probing pocket depth from the width of gingiva. Probing bone level was calculated by subtracting the distance CEJ to gingival margin from the distance gingival margin to bone.

Clinical crown length and presence of a gingival scar were the final two chairside variables. The clinical crown length was measured on the midfacial surface of the tooth from the incisal edge (or tip) to the gingival margin, parallel to the long axis of the tooth. Length was measured to the nearest 0.1 mm using an electronic caliper. Any gingival scars around the teeth were recorded.

Radiographic evaluation

Measurements of intraoral radiographs

The senior author measured root length and pulpal pathology from periapical radiographs. Root length was defined as the distance from a line connecting the mesial and distal CEJ to the root apex. The measurement was made to the nearest millimeter. Radiographic pulpal pathology in each tooth was defined as follows: *partial obliteration* – only a thin line of the pulp canal remained; *complete obliteration* – no evidence of the canal; and *pulpal necrosis* – presence of a periapical radiolucent lesion or root canal filling.¹⁷

Measurements of pretreatment panoramic radiographs

The position of the impacted tooth was determined on a panoramic radiograph. A perpendicular line was drawn from the most apical point on the incisal edge (or the cusp tip in the case of a canine) of the impacted tooth to a line connecting the incisal edges of the adjacent nonimpacted teeth (in the case of a premolar, the most occlusal cusp was used as a reference edge). The length of this perpendicular line was measured in millimeters and converted to a nonparametric scale as follows: <12mm = Mildly impacted = 1; 12-15mm = Moderately impacted = 2; >15mm = Severely impacted = 3 (Figure 3).

Table II
Visible Plaque Index and Gingival Bleeding Index
(Percentage of tooth surfaces)

	Closed-eruption (N=12)			Apically positioned flap (N=18)		
	0	1	2	0	1	2
Visible Plaque index	83%	11%	6%	79%	21%	0%
Gingival Bleeding index	58%	35%	7%	52%	41%	7%

Photographic evaluation

Intraoral end-of-treatment and recall photographic slides were projected simultaneously on side-by-side screens. Two experienced orthodontists were asked to identify the test teeth and record vertical malposition and discoloration.

Method error

The error of the clinical measurements was assessed by analyzing double sets of measures made 5 minutes apart on 10 patients selected at random. To test the error of the radiographic measurements and the evaluation of the photographic slides, duplicate evaluations were made on the records of 10 patients 2 months after the first assessment. The method errors for the probing pocket depths, gingival margin to CEJ, clinical crown length, probing attachment level, width of attached gingiva, crestal bone height, and root length were calculated using the formula:

$$Sx = \text{square root}(\Sigma D^2/2N)$$

where D = the difference between duplicate measures and N = the number of double measurements.¹⁸ The errors were 0.08 mm, 0 mm, 0.10 mm, 0.09 mm, 0.14 mm, 0 mm, and 0.5 mm respectively. The Kappa statistics calculated between the evaluations of the color slides were 0.8 for vertical discrepancies and 1.0 for color change. There were no differences between duplicate measures for plaque index, gingival index, pretreatment impaction severity, and pulpal change.

Data analysis

The apically positioned flap (N = 18) and closed-eruption (N = 12) groups were analyzed separately. Each variable was compared between the test tooth and its contralateral control. A paired two-sample t-test for means (two-tailed) was employed for the following variables: probing pocket depth, gingival margin to CEJ, clinical crown length, probing attachment level, width of attached gingiva, probing bone level, and root length. Differ-

ences between the Visible Plaque Index and Gingival Bleeding Index were tested using the Wilcoxon Signed-Rank test (two-tailed). McNemar's test (two-tailed) was used to analyze the differences between scores for pulpal changes, the presence of scarring, and the color photographs.

Results

Clinical evaluation

There were no statistically significant differences in the Visible Plaque Index and Gingival Bleeding Index between the test teeth and their contralateral controls in either group. The percentage of tooth surfaces with each index is found in Table II.

In the closed-eruption group, the attached gingiva was narrower on the distal surface, and the crestal bone was located more apically on the facial surface for the test teeth than for the controls ($P < 0.05$). No other differences were found in the closed-eruption group (Table III).

Several differences were observed in the apically positioned group (Table III). The gingival margin was located more apically on the mesial and facial surfaces ($P < 0.01$, Figure 4A), the clinical crowns were longer ($P < 0.05$, Figure 4A), more attachment was lost on the facial surface ($P < 0.05$), and more bone was lost on the mesial, facial, and distal surfaces ($P < 0.01$) for the test teeth than the controls. The attached gingiva was wider on the facial surface for the test teeth than the controls ($P < 0.01$, Figure 4C). Finally, there was significantly more gingival scarring on the test teeth relative to their controls ($P < 0.001$, Figure 4E).

Radiographic evaluation

Measurements of intraoral radiographs

In both groups the test teeth had shorter roots than their contralateral controls ($P < 0.05$, Table 4). No differences in pulpal pathology were found. However, 3 of the 18 test teeth in the apically positioned flap group showed evidence of partial obliteration. One of the 12

Table III
Clinical examination

	Closed-eruption (N=12)			Apically positioned flap (N=18)		
	Test	Control	P-value	Test	Control	P-value
Parametric variables¹						
Probing pocket depth-mesial	2.8(0.73)	3.0(0.78)	p<0.6	3.0(0.83)	3.1(0.53)	p<0.3
-facial	2.1(0.57)	2.2(0.56)	p<0.3	2.1(0.41)	2.3(0.59)	p<0.1
-distal	3.1(0.70)	2.9(0.45)	p<0.3	3.1(0.61)	3.3(0.91)	p<0.6
Gingival margin-mesial	2.3(0.78)	2.3(0.62)	p<0.6	2.1(0.67)	2.4(0.61)	p<0.01*
-facial	0.9(1.12)	1.3(0.75)	p<0.2	0.6(1.04)	1.3(0.69)	p<0.01*
-distal	2.3(0.63)	2.4(0.63)	p<0.7	2.3(0.69)	2.4(0.62)	p<0.5
Crown length-mid-facial	9.9(1.24)	9.5(1.0)	p<0.1	10.1(1.00)	9.5(0.98)	p<0.02*
Probing attachment level-mesial	-0.5(0.52)	-0.7(0.77)	p<0.6	-0.8(0.81)	-0.7(0.69)	p<0.5
-facial	-1.3(0.96)	-0.9(0.51)	p<0.2	-1.4(1.15)	-0.8(0.62)	p<0.02*
-distal	-0.8(0.58)	-0.6(0.51)	p<0.2	-0.8(0.79)	-0.7(0.77)	p<0.4
Width of attached gingiva-mesial	4.3(2.14)	4.6(1.48)	p<0.4	5.6(2.78)	4.7(1.48)	p<0.1
-facial	2.2(0.89)	2.0(1.18)	p<0.3	3.5(2.08)	1.9(0.68)	p<0.002*
-distal	3.5(1.49)	4.2(1.33)	p<0.03*	3.9(2.08)	3.8(1.60)	p<0.9
Probing bone level-mesial	1.7(0.49)	1.8(0.45)	p<0.7	2.3(0.57)	1.8(0.71)	p<0.007*
-facial	2.1(0.79)	1.6(0.51)	p<0.02*	2.4(0.98)	1.6(0.61)	p<0.002*
-distal	1.8(0.45)	1.6(0.51)	p<0.2	2.2(0.62)	1.7(0.57)	p<0.007*
Nonparametric variables²						
Gingival scarring						
-No scarring	8(66.7%)	12(100%)	p<0.1	1(5.5%)	17(94.5%)	p<0.001*
-Mesial scar only	—	—	—	2(11%)	—	—
-Distal scar only	4(33.3%)	—	—	5(28%)	1(5.5%)	—
-Mesial + Distal scars	—	—	—	9(50%)	—	—
-All three surfaces	—	—	—	1(5.5%)	—	—

*Statistically significant, p<0.05

¹Values given in millimeters, with standard deviations in ()

²Number of teeth, with percentage of teeth in ()

teeth treated with closed-eruption had a root canal filling. This patient had a pin placed during the surgical procedure. The remaining teeth had normal pulps.

Measurement of pretreatment panoramic radiographs

The majority of canines and centrals in the closed-eruption group were scored as moderately impacted. In the apically positioned group, the majority of the centrals were severely impacted, while the canines were evenly distributed between mild, moderate, and severe (Table 4).

Photographic evaluation

No differences were found in the closed-eruption group (Table 5). However, one of the 12 test teeth could not be evaluated from the photograph. Of the remaining 11, the tooth with placement of a pin during surgery demonstrated color change. Vertical (intrusive) relapse was seen in four test teeth and one con-

trol tooth.

The apically positioned flap group showed differences in vertical position between test and control teeth (P<0.001, Table V). Eleven of the test teeth relapsed apically from their end-of-treatment position (Figure 4C and E). None of the control teeth showed any change in vertical position from the end-of-treatment to the time of recall.

Discussion

This investigation showed that the gingival margins on the mesial and facial surfaces of the test teeth were positioned farther apically relative to the nonoperated teeth in the apically positioned flap group. This finding differs from those of Vanarsdall and Corn³ who did not report differences in the position of the labial gingival margins after apically positioned flap surgery. However, Woloshyn and colleagues¹⁹ found recession consistently after uncovering palatally impacted canines. The

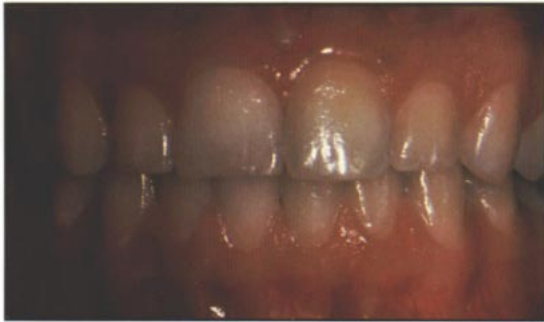

Figure 4A

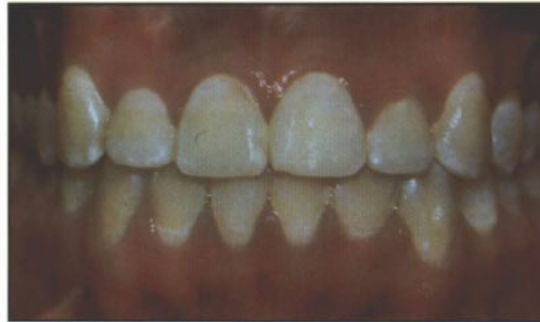

Figure 4B

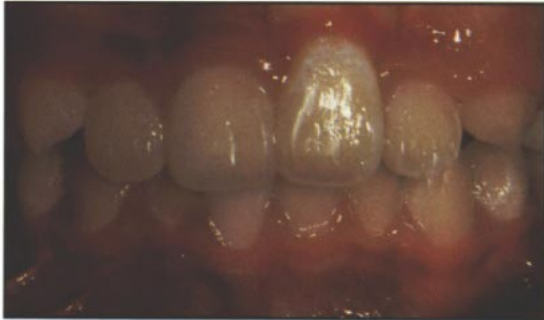

Figure 4C

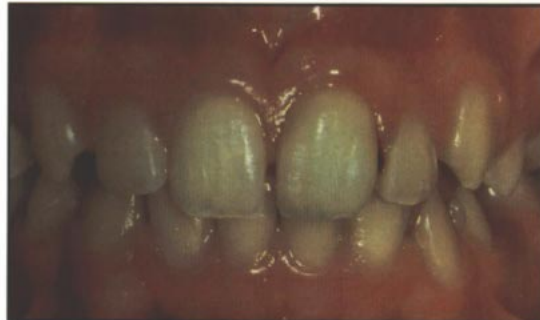

Figure 4D

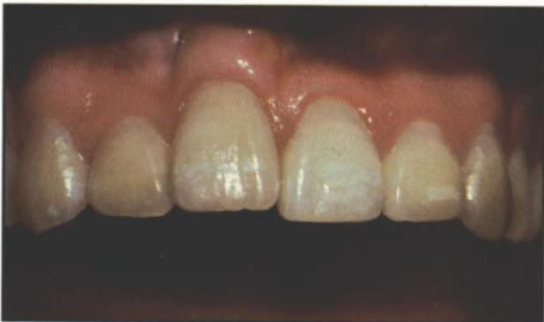

Figure 4E

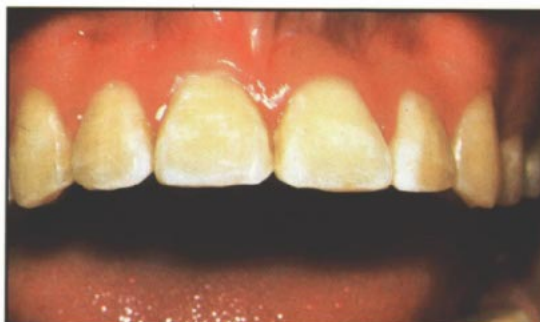

Figure 4F

Figure 4
Recall photographs of labially impacted central incisors uncovered with an apically positioned flap (left column) and a closed-eruption technique (right column).

A: Mildly impacted maxillary left central incisor, uncovered with an APF, demonstrating apical gingival margin heights and increased clinical crown length relative to its contralateral control.

B: Mildly impacted maxillary left central incisor uncovered with a CE technique, with gingival margin heights and crown length similar to its control.

C: Moderately impacted maxillary left central incisor, uncovered with an APF, demonstrating greater width of attached gingiva and a more superior incisal edge than its control.

D: Moderately impacted maxillary left central incisor, uncovered with a CE technique, with a width of attached gingiva and a vertical position similar to its control.

E: Severely impacted maxillary right central incisor, uncovered with an APF, demonstrating gingival scarring.

F: Severely impacted maxillary right central incisor uncovered with a CE technique, essentially indistinguishable from its control.

differences between test and control teeth in the present study were statistically significant, but probably not clinically significant, since only four of the test teeth had exposure of the cemento-enamel junction on the facial surface.

In the present study the clinical crown length of the test teeth was greater than the nonoperated controls in the apically positioned flap group. This variable has not been measured in previous studies of labially impacted teeth uncovered with the apically positioned flap technique.³⁻⁶ The higher tendency for apical gingival position and greater clinical crown length produce uneven anterior gingival margins and may be unesthetic in the patient with a high smiling lip line. Neither of these problems were observed in the teeth treated with the closed-eruption technique.

Loss of attachment was found on the facial surfaces of the test teeth in the apically positioned flap group. This problem did not occur

in patients treated with the closed-eruption technique. These findings differ from those of Vanarsdall and Corn,³ but are consistent with studies of palatally impacted canines.¹⁹⁻²³ A likely explanation is that a labially impacted tooth might have a thinner labial plate of bone, and therefore have a greater risk of attachment loss if uncovered with an apically positioned flap.²⁴ This potential for attachment loss would not be as great with the closed-eruption technique. The increased potential of plaque accumulation around teeth exposed with an apically positioned flap could also explain this difference in outcome between the two techniques.

The bone height on the facial surfaces was more apical on the test teeth than the controls in both the closed-eruption and apically positioned flap groups. Although bone loss was observed in both groups, loss of attachment was seen only in the apically positioned flap

Table IV
Radiographic examination

	Closed-eruption (N=12)			Apically positioned flap (N=18)		
Periapical variables ¹	Test	Control	P-value	Test	Control	P-value
Root length	15.4(3.5)	16.2(3.3)	p<0.03*	16.1(4.2)	17(4.6)	p<0.004*
Panoramic variables ²						
Pretreatment impaction severity	Mild	Moderate	Severe	Mild	Moderate	Severe
-Centrals						
a. Tooth #8	—	—	1(16.7%)	1(16.7%)	—	1(16.7%)
b. Tooth #9	1(16.7%)	3(50%)	1(16.7%)	1(16.7%)	1(16.7%)	2(33.3%)
-Canines						
a. Tooth #6	—	2(33.3%)	2(33.3%)	2(18.2%)	3(27.3%)	1(9%)
b. Tooth #11	—	2(33.3%)	—	2(18.2%)	1(9%)	2(18.2%)
-Lateral						
a. Tooth #7	—	—	—	1(100%)	—	—

*Statistically significant, p<0.05
¹Values given in millimeters, with standard deviations in ()
²Number of teeth, with percentage of specific tooth type in ()
 Pretreatment impaction severity: Mild: <12 mm; Moderate: 12-15 mm; Severe: >15 mm

group. However, the amount of attachment and bone loss may not be considered clinically significant in either group.

The width of attached gingiva was greater on the facial surface of the test teeth than the controls in the apically positioned flap group. In the closed-eruption group, the width of attached gingiva was narrower over the operated teeth. Several studies have investigated the value of an adequate zone of attached gingiva.²⁵⁻³⁰ A wider zone of attached gingiva may prevent gingival recession. However, in the present study, the apically positioned flap group showed apical migration of the gingival margin, bone loss, and attachment loss even though the zone of attached gingiva was wider than the control teeth. Possibly an apically positioned flap accelerates the passive apical migration of the labial epithelial attachment. In contrast, a tooth uncovered with closed-eruption would duplicate natural tooth eruption with a relatively delayed passive migration of the labial gingival margin.

The presence of gingival scarring was a significant finding in the apically positioned flap group. These soft tissue bands may produce an unesthetic appearance if the patient has a high smiling lip line. These problems have not been addressed in previous studies.^{3-6,9} In those teeth uncovered with an apically positioned flap, 90% had gingival scars compared with 6% of the controls. Half of these test teeth had noticeable soft tissue bands on both me-

sial and distal surfaces. However, in the closed-eruption group, no difference between operated and nonoperated teeth was found, demonstrating a lack of scarring with this procedure. The difference may be due to the surgical procedure. In the apically positioned flap procedure, the gingiva (positioned apically) heals and attaches to the adjacent mucosa. As the mucosal tissue is pulled incisally during eruption, a vertical band of mucosa is pulled down toward the alveolar crest. The higher the impaction, the more apically positioned the flap, resulting in a longer, more noticeable band of mucosa. This mucosal artifact does not occur in the closed-eruption technique since the flap is sutured back into its original position.

The present study showed significant intrusion of operated teeth relative to controls in the apically positioned flap group. Following orthodontic treatment, over 61% of the test teeth had intruded. This problem was not seen in the closed-eruption group. The finding is consistent with previous reports of palatally impacted canines which showed significant vertical relapse.^{19,22} Although the cause of intrusion is not known, it may be related to the positioning of the gingival flap during surgery. If the flap is positioned high above the mucogingival junction, it will heal to the adjacent mucosa. As the uncovered tooth is erupted orthodontically, the mucosa will stretch and may produce a tendency for verti-

Table V
Photographic examination

	Closed-eruption (N=12)		Apically positioned flap (N=18)		
Photographic variables ¹					
-Color change	1(9%)	0(0%)	—	0(0%)	0(0%)
-Vertical relapse	4(12%)	1(8%)	p<0.06	11(61%)	0(0%)

*Statistically significant, p<0.05

¹Number of teeth, with percentage of teeth in ()

cal relapse after appliance removal.

In both groups, test teeth had shorter roots than their contralateral controls. Previous studies have noted that root resorption may be associated with the distance the root moves through the bone.³¹⁻³³ However, the severity of impaction did not appear to influence root length in our sample. Possibly impacted teeth have inherently shorter roots. This hypothesis could not be tested in this study.

Although this study has reported several significant findings, some limitations should be mentioned. First, the sample did not allow direct comparisons between the two surgical techniques since the two groups could not be strictly matched. Second, a larger sample size would allow segregation of the groups according to pretreatment severity of impaction. This would help to elucidate the role of initial tooth position on the periodontal and esthetic outcomes of treatment. Finally, the method error for the clinical variables was small in this study. This could suggest examiner bias since all measurements were performed at only one session. However, the test and control teeth were in the same subject, and since they were exposed to the same bias, this would maximize the accuracy of comparisons between the two teeth.

It is apparent from the results of this study that more periodontal and esthetic disadvantages may be expected with the apically positioned flap technique than with the closed-eruption technique. Accordingly, the indications for use of the apically positioned flap technique may be questioned. The vertical and horizontal position of the impacted tooth and the amount of gingiva have been used by some surgeons to determine the appropriate technique.⁸ If the tooth is impacted in the middle of the alveolus or high in the vestibule near the nasal spine, the closed-eruption technique may be the treatment of choice.¹⁰⁻¹³ However, if the tooth requires more attached

gingiva or is displaced lateral to the edentulous area, an apically positioned flap may be the best choice.⁸ Future studies are needed to validate these suggested criteria.

Conclusions

1. Labially impacted maxillary anterior teeth uncovered with an apically positioned flap technique have more unesthetic sequelae than those uncovered with a closed-eruption technique.

2. Negative esthetic effects, such as increased clinical crown length, increased width of attached tissue, gingival scarring, and intrusive relapse were evident in the teeth treated with an apically positioned flap.

3. Periodontal attachment differences between uncovered and contralateral control teeth were not clinically significant in either the apically positioned flap or closed-eruption groups.

Acknowledgments

The authors would like to thank Jon Årtun, DDS, Dr. Odont., and Rutger Persson, DDS, Dr. Odont., for serving as research advisors. This research was supported by the Washington Dental Service Foundation and the University of Washington Orthodontic Alumni Association.

Author Address

Dr. Vincent Kokich
Department of Orthodontics
University of Washington, SM-46
Seattle, WA 98195
M.E. Vermette is in private practice in Concord, New Hampshire.

V.G. Kokich is Professor, Department of Orthodontics, University of Washington, Seattle, Washington.

D.B. Kennedy is in private practice in Vancouver, British Columbia.

References

1. Bass T. Observation of the misplaced upper canine tooth. *Dent Pract* 1967; 18:25.
2. Johnston W. Treatment of palatally impacted canine teeth. *Am J Orthod* 1969; 56:589-596.
3. Vanarsdall R, Corn H. Soft tissue management of labially positioned unerupted teeth. *Am J Orthod* 1977; 72:53-64.
4. Duncan WK, Ashrafi MH, Meister F, and Pruhs RJ. Management of the nonerupted maxillary anterior tooth. *J Am Dent Assoc* 1983;106:640-644.
5. Boyd RL. Clinical assessment of injuries in orthodontic movement of impacted teeth. II. Surgical recommendations. *Am J Orthod* 1984;86:407-418.
6. Bishara S. Impacted maxillary canines: a review. *Am J Orthod Dentofac Orthop* 1992;101:159-171.
7. Gaulis R, Joho JP. Parodonte marginale de canines superieures incluses: Evaluation suite a differentes methodes d'acces chirurgicales et de systeme orthodontique. *SSO*. 1978; 6:1249-1259.
8. Kokich VG, Mathews DP. Surgical and orthodontic management of impacted teeth. *Dent Clin North Am* 1993; 37(2):181-204.
9. Crescini A, Clauser C, Giorgetti R, Cortellini P, Pini Prato GP. Tunnel traction of infraosseous impacted maxillary canines. A three-year periodontal follow-up. *Am J Orthod Dentofac Orthop*. 1994;105:61-72.
10. Fournier A, Turcotte J, Bernard C. Orthodontic considerations in the treatment of maxillary impacted canines. *Am J Orthod* 1982;81:236-239.
11. Hunter S. Treatment of the unerupted maxillary canine. *Br Dent J* 1983;154:294-296.
12. Magnusson H. Saving impacted teeth. *J Clin Orthod* 1990;XXIV(4):246-249.
13. Wong-Lee T, Wong F. Maintaining an ideal tooth-gingiva relationship when exposing and aligning an impacted tooth. *Br J Orthod* 1985;12:189-192.
14. Ainamo J and Bay I. Problems and proposals for recording gingivitis and plaque. *Int Dent J* 1975; 25: 229-235.
15. Fassek T, Morgenroth K. Comparative stomatographic and histochemical studies of the marginal gingiva in men. *Parodontologie*. 1958; 12: 151-160.
16. Greenberg J, Laster L, Listgarten MA. Transgingival probing as a potential estimator of alveolar bone level. *J Periodontol* 1976; 47: 514-517.
17. Jacobsen I, Kerekes K. Long-term prognosis of traumatized permanent anterior teeth showing calcifying processes in the pulp cavity. *Scand J Dent Res* 1977; 85: 588-598.
18. Dahlburg G. Statistical methods for medical and biological students. London: George Allen and Unwin Ltd., 1940; 122-132.
19. Woloshyn H, Årtun J, Kennedy DB, Joondeph DR. Pulpal and periodontal reactions to orthodontic alignment of palatally impacted canines. *Angle Orthod*. In press.
20. Hansson C, Linder-Aronson S. Gingival status after orthodontic treatment of impacted upper canines. *Trans Eur Orthod Soc* 1972;48:433-441.
21. Wisth PJ, Norderval K, Boe OE. Periodontal status of orthodontically treated impacted maxillary canines. *Angle Orthod* 1976;46:69-76.
22. Becker A, Kohavi D, Zilberman Y. Periodontal status following the alignment of palatally impacted canine teeth. *Am J Orthod* 1983;84:332-336.
23. Boyd RL. Clinical assessment of injuries in orthodontic movement of impacted teeth. I. Methods of attachment. *Am J Orthod Dentofac Orthop* 1982;82:478-486.
24. Årtun J, Osterberg SK, Joondeph DR: Long-term periodontal status of labially erupted canines following orthodontic treatment. *J Clin Periodontol* 1986;13:856-861.
25. Lang NP, Löe H. The relationship between the width of keratinized gingiva and gingival health. *J Periodontol* 1972;43(10):623-627.
26. Rose ST, App GR. A clinical study of the development of the attached gingiva along the facial aspect of the maxillary and mandibular anterior teeth in the deciduous, transitional and permanent dentitions. *J Periodontol* 1973;44:131-138.
27. Heaney TG. Periodontal problems associated with surgical exposure of unerupted teeth. *Br J Orthod* 1976;3(2):79-85.
28. Boyd RL. Mucogingival considerations and their relationship to orthodontics. *J Periodontol* 1977;49:67-76.
29. Dorfman HS, Kennedy JE, Bird WC. Longitudinal evaluation of free autogenous gingival grafts. *J Clin Periodontol* 1980;7:316-324.
30. Coatoam GW, Behrents RG, Bissada NF. The width of keratinized gingiva during orthodontic treatment: its significance and impact on periodontal status. *J Periodontol* 1981;52(6):307-313.
31. Linge BO, Linge L. Apical root resorption in upper anterior teeth. *Eur J Orthod* 1983;5:173-83.
32. Linge L, Linge BO. Patient characteristics and treatment variables associated with apical root resorption during orthodontic treatment. *Am J Orthod Dentofac Orthop* 1991;99:35-43.
33. Mirabella AD, Årtun J. Risk factors for apical root resorption of maxillary anterior teeth in adult orthodontic patients [thesis]. Seattle:University of Washington, 1993.