

Prediction of mandibular growth rotation

A. Björk, Odont. Dr.

Copenhagen, Denmark

The introduction of cephalometric radiography 37 years ago initiated new trends in orthodontics, as is witnessed by a wealth of articles in this JOURNAL over the years. As a tribute to Dr. Pollock, editor of the JOURNAL for half a century, I am pleased to have the opportunity of offering a contribution on this subject. It will take the form of an outline of some results of studies of craniofacial growth in children, in which metallic implants have been inserted in the jaws to serve as fixed reference points. Clinical applications arising from these studies will also be touched upon.

The technique whereby metal implants are inserted in bone has been used in animals for more than a century, but the application of the method in craniometric studies of growth in man is of more recent date. Our investigation, which was begun in 1951, comprises a mixed longitudinal study of about 100 children of each sex covering the age period from 4 to 24 years.^{6, 9, 14} The sample consists of normal children with and without malocclusion and also children with pathologic conditions. By means of the implant method, and within its inherent limitations, it is possible to locate sites of growth and resorption in the individual jaws and to examine individual variations in direction and intensity. The marker technique has also proved useful in the analysis of the mechanisms underlying changes in the intermaxillary relationship during growth, an analysis that has led to a radical modification of previous views. This applies in particular to the vertical jaw relation, since the implant technique detects considerably greater rotation of the mandible during growth than may be observed with conventional methods. Mandibular growth rotation will therefore be the main topic of this presentation.

From the Orthodontic Department, Royal Dental College, Copenhagen, Denmark.
This article is based on investigations supported by Research Grant HS 154 from the National Institute of Child Health and Human Development, National Institutes of Health, Bethesda, Md.

Since the information gained by the implant technique should be regarded as supplementary to that obtained from conventional x-ray examinations, the results obtained by the two methods will be compared. As the invitation to present this article requested personal views on procedures and perspectives in orthodontics and a survey of original contributions in the field, the references are essentially limited to reports from this Department. The article is also based on experience with the implant method that cannot be documented here.

Average versus individual growth pattern

At the time when x-ray cephalometry was introduced, research was concerned primarily with the *average* growth changes in form of the head and face. Represented by measurements or by tracing, the facial form showed comparatively small changes with age in such studies performed as far back as the early 1930's.^{1, 19} It is hardly surprising, therefore, that the development in form of the face was conceived as being relatively static, except in pathologic or otherwise extreme cases. A given intermaxillary relation, for instance, was then considered as being static throughout the period of growth. The treatment of malocclusion, therefore, was thought to be essentially independent of age, sex, or maturation rate. This view of the facial development is perhaps one of the main reasons that, in spite of the introduction of highly efficient appliance systems in treatment, due regard has not always been given to the individual variability of growth. This applies to both fixed and removable appliances.

As a result of longitudinal studies in which x-ray cephalometry was applied, it was recognized that there are considerable individual differences in the development of facial form and in intermaxillary relations. It was further realized that these *individual* growth changes in shape are the rule rather than the exception. The changes in form during growth were found to follow a Gaussian distribution and, as mentioned above, even though they are on the average quite small, they include extreme types which do not necessarily have a pathologic origin.²

It is clearly important to have complete statistical data for the normal range of variation of facial changes throughout the whole period of growth, but at present such data are available only for limited periods. I would like here to refer to a follow-up study of a random sample of 243 Swedish boys first examined by the lateral x-ray cephalometric method at 12 years of age and again at 20 years. In general, the range of the individual changes in both form and size of the facial skeleton that took place in this period was roughly half the range of form or size at adult ages.^{5, 17} In the dentition, still greater individual growth changes were found; for overbite, these amounted to 78 per cent of the total range at adult ages.³

A cephalometric radiograph from a single stage of development is undoubtedly of great value in facilitating a morphologic analysis of the facial structures. It is evident, however, that the younger the child, the more difficult it is to assess the final facial form from such a morphologic analysis. If the treatment is delayed until the end of the growth period, it is obvious what morphologic

problems are involved, but the possibility of introducing therapeutic measures earlier, when they could have been more effective, has then been lost. If an attempt is made to assess the growth trend at an early stage, this information can be used in designing the treatment or evaluating the problems that may arise before growth is completed. A growth analysis consists essentially of three items, each of which is clinically significant: (1) an assessment of the development in *shape* of the face which, in the first place, implies changes in the intermaxillary relationship,¹⁷ (2) an assessment of whether the *intensity* of the facial growth in general is high or low,⁴ and (3) an evaluation of the individual rate of *maturation*. This last item is important in establishing whether puberty has been reached and when the growth may be expected to be completed.¹⁵

Before discussing growth changes in shape of the face related to growth rotation of the mandible, I shall first outline what has been learned about the growth pattern of the mandible from our implant studies.

Mandibular growth pattern. It has been confirmed by the implant technique that growth in length of the mandible in man occurs essentially at the condyles.^{6, 11} The anterior aspect of the chin is extremely stable, no growth having been found here except in a few cases of pathologic development. The thickening of the symphysis, therefore, normally takes place by apposition on its posterior surface. On its lower border there is likewise apposition, which contributes to the increase in height of the symphysis. As the endosteal resorption in this area does not occur at the same rate as the apposition on the outer surface, a pronounced apposition will be reflected in an increase in the thickness of the cortical substance. The periosteal apposition below the symphysis is extended posteriorly, to the anterior part of the lower border of the mandible, and when it is marked this area is characteristically rounded. Below the angle of the mandible there is normally resorption, which may be very pronounced. In some cases there is, instead, apposition on the lower border at the angle of the jaw. These appositional and resorptive processes result in an individual shaping of the lower border of the mandible, which characterizes the type of growth.

The growth at the condyles usually does not occur in the direction of the ramus, as is commonly imagined, but slightly forward. Individual variations in the direction of growth at the condyles are large and, in the adolescent period, have been found to vary by almost 45 degrees. Growth is not always linear in direction but usually curves slightly forward or occasionally even backward. The pattern of mandibular growth is thus generally characterized by an upward- and forward-curving growth at the condyles, while at the same time there is resorption on the lower aspect of the gonial angle and some apposition below the symphysis. The mandibular canal is not remodeled to the same extent as the outer surface of the jaw, and the trabeculae related to the canal are therefore relatively stationary. The curvature of the mandibular canal, therefore, reflects the earlier shape of the mandible.

The lower border of a developing molar germ in the mandible appears to be fairly stationary until the roots begin to form. This means that, for a period,

the tooth germ may serve as a natural reference structure in the growth analyses of the mandible.

Growth prediction

If we admit the importance of being able to predict the growth pattern, what possibilities do we have at our disposal for doing so? So far as development in shape is concerned, three methods may be distinguished. These may be referred to as *longitudinal*, *metric*, and *structural*. The last of these has been developed from the implant studies.

Prediction by the *longitudinal* method, which is commonly used, consists of following the course of development in annual x-ray cephalometric films.^{7, 12} In some cases it may be useful to start the observation prior to treatment, but usually it is desirable to initiate treatment early and, in the meantime, to accumulate experience of the current type of growth to serve as a basis for planning the subsequent measures. It is for the subjects displaying the most pronounced changes in facial form that the diagnosis of the growth pattern is of prime clinical importance. In the period of most rapid growth this may be established within a year or two.

The longitudinal method has a general limitation in that the pattern of growth is not constant and the pattern recorded at a juvenile age may well have changed by adolescence.

A particular limitation of the longitudinal method is that, whereas it permits the observation of changes in the sagittal jaw relation with growth, those changes occurring in the vertical jaw relation are, to a large extent, masked. As the implant method reveals, this difference is due to the fact that there is no major remodeling of the anterior surfaces of the jaws during growth, whereas the horizontal surfaces of reference, such as the nasal floor and especially the lower border of the mandible, undergo radical restructuring.^{11, 13} Because of this, changes in prognathism of the jaws can be recorded to a high level of exactness by the conventional longitudinal technique. On the other hand, changes in the vertical position of the jaws, in the form of rotation, give the impression of being considerably smaller when judged by conventional longitudinal x-ray analysis with the lower border of the mandible as a reference than they, in fact, are when assessed with the aid of metallic implants. This affects the correlation analyses of the vertical facial development.^{22, 25} It also affects the comparisons of normal and pathologic development.²⁰

For clinical purposes, the analysis of the vertical development of the face may be improved by using what can be called natural reference structures in the mandible, as illustrated by Fig. 1. By superimposing two radiographs taken at different ages and orienting them with reference to these structures, one may estimate the growth pattern of the mandible with a fairly high degree of accuracy. The growth rotation of the mandible in relation to the cranial base can then be read from the angle between the nasion-sella lines for the two ages.

The *metric* method aims at a prediction of facial development on the basis of the facial morphology, determined metrically from a single x-ray film. However, statistical studies of the possibility of predicting the intensity or direction

of subsequent development from size or shape at childhood indicate that this is not feasible, no matter which system of cephalometric analysis has been used.^{3, 5, 17-19}

In the material on Swedish boys for whom profile radiographs were obtained at 12 and 20 years of age, there were only extremely weak correlations, if any, between the dimensions of the face at 12 years and their residual growth.^{5, 17} Thus, the growth in the length of the mandible during adolescence could not be judged from its size before puberty. The changes in shape of the face during adolescence, expressed in terms of angular measurements, were also, at most, very weakly correlated with the shape of the face at 12 years of age, which is an age at which treatment often is instituted or planned.

It is known that, on the average, mandibular prognathism increases with age and that the range of variation is large; individually, there may be a very large increase, but occasionally even a decrease is seen. A harmonic sagittal jaw relation may thus develop into a disharmonic one, and vice versa.

So far as the prediction of vertical development of the face is concerned, the metric method has not proved more suitable. As determined from its lower border, the mandible on the average rotates forward a little during adolescence, and its inclination thus decreases. Individually, this decrease may be extremely pronounced, but occasionally there may even be an increase in the inclination. In the Swedish series there was only a weak correlation ($r = 0.22$) between the inclination of the mandible at 12 years and its rotation during adolescence. The inclination prior to puberty thus affords no guide in prediction.

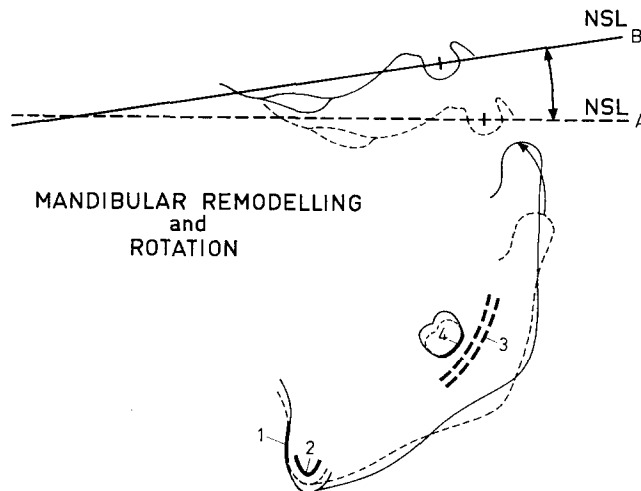


Fig. 1. Longitudinal method of analysis of mandibular growth rotation from the angle between the nasion-sella lines, at two stages (A and B) after superimposition of the mandibles on natural reference structures: tip of the chin (1), inner cortical structure at the inferior border of the symphysis (2), trabecular structures related to the mandibular canal (3), and the lower contour of a molar germ (4) from the time mineralization of the crown is visible until the roots begin to form.

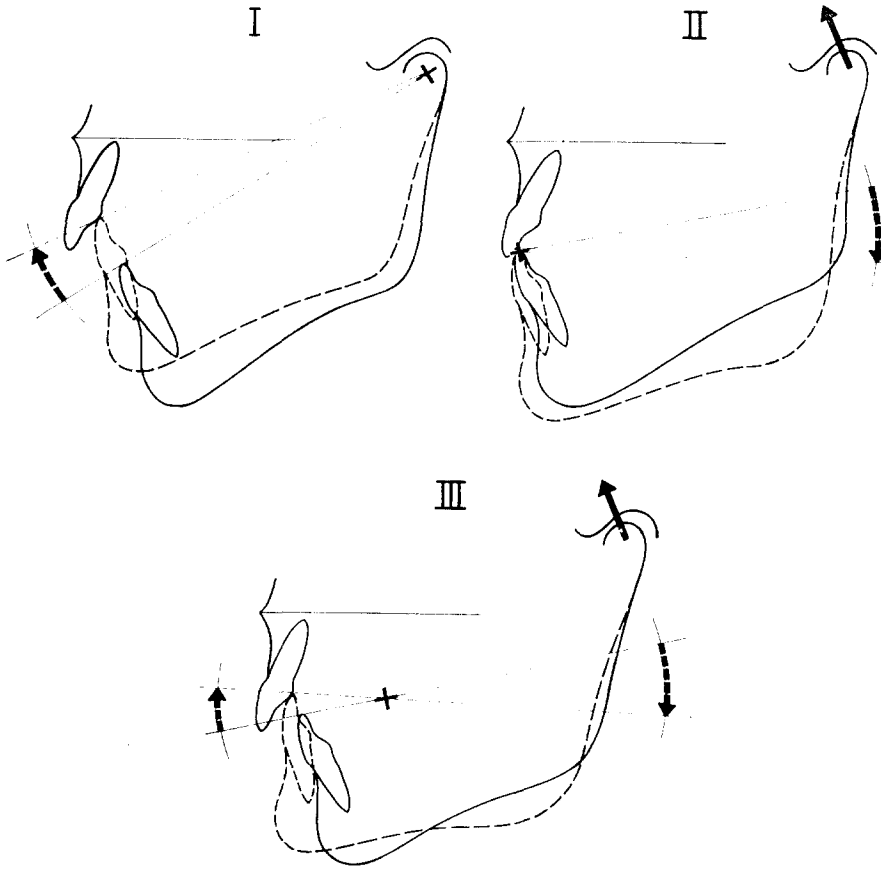


Fig. 2. Forward rotation of the mandible with the center at the joints (I), with the center at the incisal edges of the lower incisors (II), and with the center at the premolars (III).

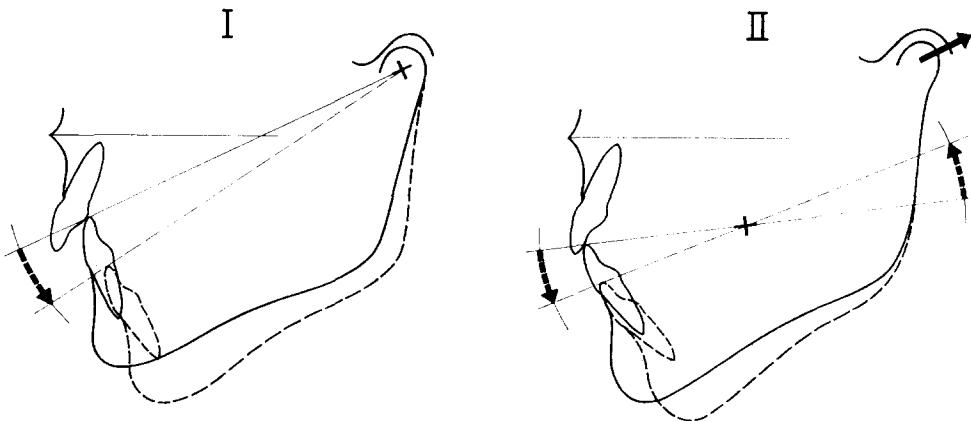


Fig. 3. Backward rotation of the mandible with the center at the joints (I) and with the center at the last occluding molars (II).

The *structural* method is based on information concerning the remodeling processes of the mandible during growth, gained from the implant studies.¹¹ Without the use of implants, prediction of the vertical development of the face insofar as it concerns mandibular growth rotation may then be possible from a single radiograph. The principle is to recognize specific structural features that develop as a result of the remodeling in a particular type of mandibular rotation. A prediction of the subsequent course is then made on the assumption that the trend will continue. Such structural signs will be detailed below. First, however, the mechanism underlying the mandibular rotation and the centers of rotation will be considered.^{10, 12}

From the standpoint of growth, the mandible may be regarded as a more or less unconstrained bone, for it may change its inclination in several ways. A critical factor in this respect is the site of the center of rotation, which may be located at the posterior or anterior ends of the bone or somewhere in between, in which case the ends of the mandible swing in different directions. Thus, the center may not necessarily lie at the temporomandibular joints, as is usually imagined, although this is not readily evident from examination by conventional techniques. There follows a schematic account of the various types of rotation of the mandible that may be recognized with the implant method, as illustrated by Figs. 2 and 3 and exemplified in Figs. 4 and 5.

Forward rotation may occur in the following three ways :

Type I. In this type (the one that is usually considered) there is a forward rotation about centers in the joints which gives rise to a deep-bite, in which the lower dental arch is pressed into the upper, resulting in underdevelopment of the anterior face height. The cause may be occlusal imbalance due to loss of teeth or powerful muscular pressure. This lowering of the bite may occur at any age.

Type II. Forward growth rotation of the mandible about a center located at the incisal edges of the lower anterior teeth is due to the combination of marked development of the posterior face height and normal increase in the anterior height. The posterior part of the mandible then rotates away from the maxilla.

The increase in the posterior face height has two components. The first is the lowering of the middle cranial fossae in relation to the anterior one as the cranial base bends, the condylar fossae then being lowered. The second component is the increase in the height of the ramus, which is pronounced in the case of vertical growth at the mandibular condyles. Only the latter component, which is the larger one, is illustrated in Fig. 2, and is described below.

Because of the vertical direction of condylar growth, the mandible is lowered more than it is carried forward. Because of the muscular and ligamentous attachments, the lowering takes place as a forward rotation in relation to the maxilla, with the center at the incisal edges of the lower incisors. The eruption of the molars keeps pace with the rotation. Because of the simultaneous marked resorption below the gonial angle, the height in this region may not increase to a great extent and the lower border undergoes a characteristic remodeling.

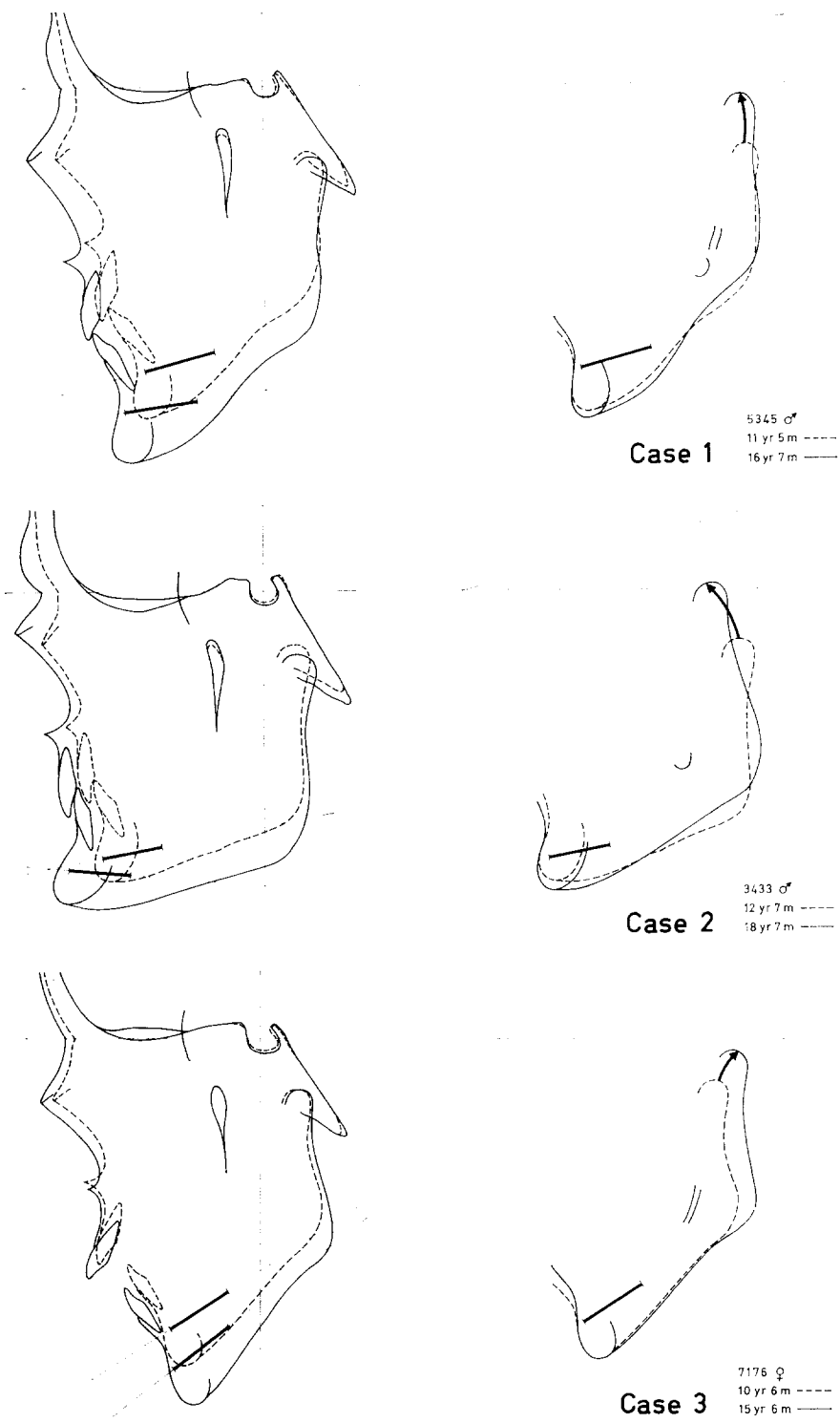


Fig. 4. For legend, see opposite page.

Type III. In anomalous occlusion of the anterior teeth the forward rotation of the mandible with growth changes its character. In the case of large maxillary overjet or mandibular overjet, the center of rotation no longer lies at the incisors but is displaced backward in the dental arch, to the level of the premolars. In this type of rotation the anterior face height becomes underdeveloped when the posterior face height increases. The dental arches are pressed into each other and basal deep-bite develops.

In the growth rotation of Types II and III the mandibular symphysis swings forward to a marked degree, and the chin becomes prominent. This is one of the reasons for the chin formation characteristic of man.

The inclination of the teeth is also greatly influenced by the rotation of the jaw. The position of the lower incisors seems to be functionally related to the upper incisors, as is reflected in the fact that the interincisor angle undergoes a smaller change than the rotation of the jaw. As a result, the incisors in their eruption are guided forward and there is an increase in the alveolar prognathism right down to the apical zone. This is contrary to the impression given by the jaw profile. The rotation, however, also displaces the paths of eruption of all the teeth in the mesial direction, thereby tending to create crowding in the anterior segment through what may be referred to as "packing."

The rotation also affects the position of the lower posterior teeth in relation to the upper teeth. Forward growth rotation thus causes the lower posterior teeth to be more upright than usual in relation to the upper posterior teeth, with an increase in what may be called interpremolar and intermolar angles.

Backward rotation of the mandible is less frequent than forward rotation and has been examined by the implant method in considerably fewer subjects. Two types have been recognized:

Type I. Here the center of the backward rotation lies in the temporomandibular joints. This is the case when the bite is raised by orthodontic means, by a change in the intercuspation or by a bite-raising appliance, and results in an increase in the anterior face height.

Backward rotation of the mandible about a center in the joints also occurs in connection with growth of the cranial base. In the case of flattening of the cranial base, the middle cranial fossae are raised in relation to the anterior one, and then the mandible is also raised. There may be other causes also, such as an incomplete development in height of the middle cranial fossae, as in oxycephaly. This underdevelopment of the posterior face height leads to a

Fig. 4. Cases illustrating the three types of growth rotation of the mandible related to the condylar growth direction. An indicator line is drawn through two implants in the mandible in each case. No orthodontic treatment was performed during the observation period. **Case 1:** Forward growth rotation, Type II. Normal incisal occlusion and normal development of anterior face height. **Case 2:** Forward growth rotation, Type III. Development of basal deep-bite and underdevelopment of anterior face height. **Case 3:** Backward growth rotation, Type II. Development of basal open-bite and overdevelopment of anterior face height.

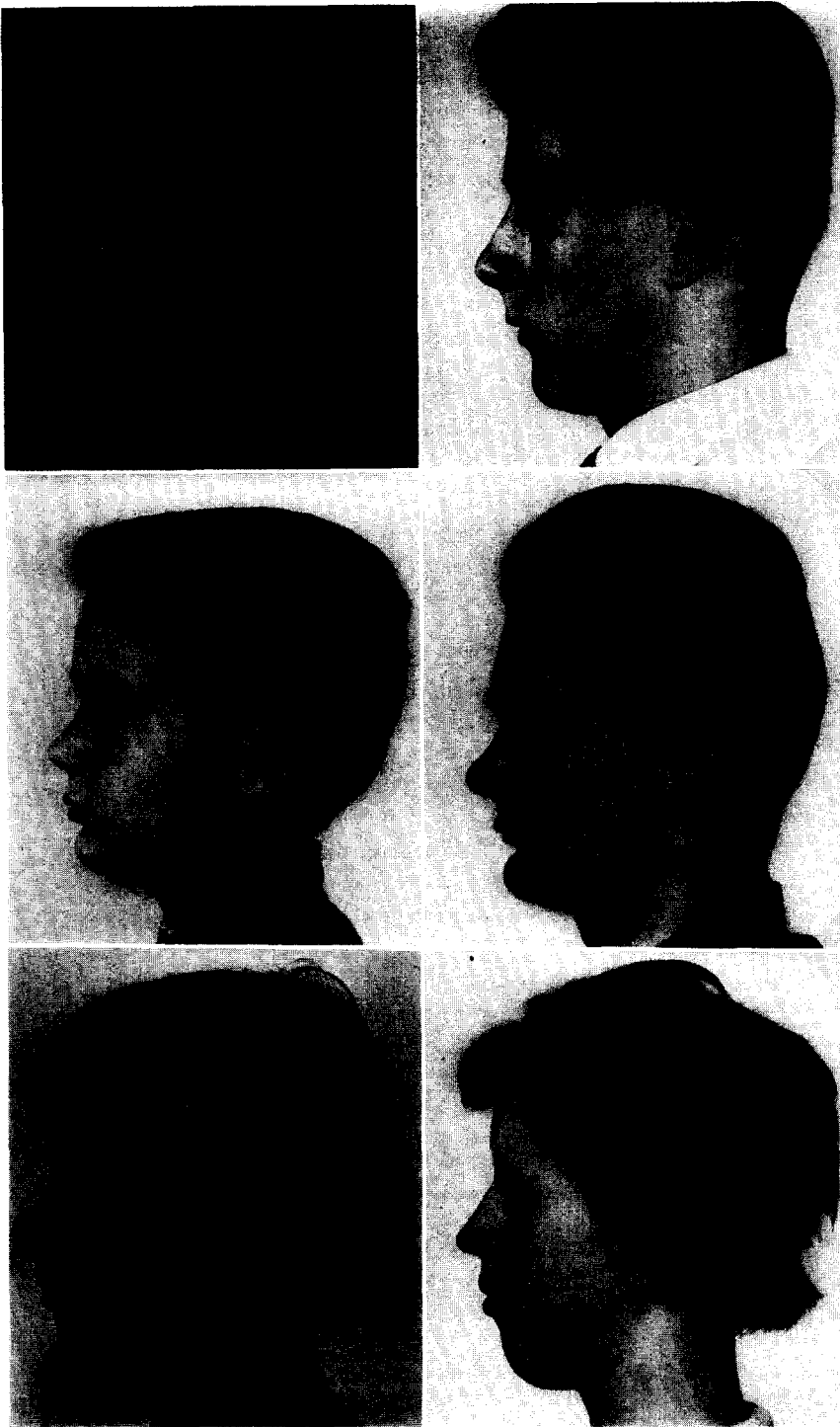

Fig. 5. Photographs illustrating facial development in the cases described in Fig. 4.

backward rotation of the mandible, with overdevelopment of the anterior face height and possibly open-bite as a consequence. The mandible is, in principle, normal.

Type II. Backward rotation here occurs about a center situated at the most distal occluding molars. This occurs in connection with growth in the sagittal direction at the mandibular condyles. In the subjects analyzed so far, the direction of this sagittal growth has curved increasingly backward. As the mandible grows in the direction of its length it is carried forward more than it is lowered in the face, and because of its attachment to muscles and ligaments it is rotated backward.

Because of the position of the center of rotation at the molars, the symphysis is swung backward and the chin is drawn back below the face. The soft tissues of the chin may not follow this movement, and a characteristic double chin can form. Basal open-bite may develop, and there is difficulty in closing the lips without tension. Since the position of the lower incisors, as mentioned earlier, is functionally related to the upper incisors, they become retroclined in the mandible and the alveolar prognathism is reduced.

The lateral teeth are not guided distally in their eruption to the same extent, and crowding tends to develop in the anterior segment of the lower arch.

The fact that in the subjects submitted to analysis the eruption of the lower molars was hindered at the point of rotation indicates that the cause of the rotation did not lie in overeruption of these teeth. Because of the backward rotation of the mandible, the interpremolar and intermolar angles are small, which means that the premolars and molars are inclined forward in relation to the maxillary ones, and usually to a pronounced degree, because of the close proximity of these teeth to the center of rotation.

This type of backward rotation has been found to be characteristic also in cases of various forms of condylar hypoplasia.^{8, 16} In condylar aplasia, the condition seems to be even more complex.

There is an obvious relationship between the type of rotation of the mandible and the direction of condylar growth. The explanation for this remains to be found, but it is evident that muscular factors play an important part.²³

Structural signs of growth rotation

From the clinical standpoint, it is important to detect extreme types of mandibular rotation occurring during growth. Seven structural signs of extreme growth rotation will be considered in relation to the condylar growth direction. Not all of them will be found in a particular individual, but the greater the number that are present, the more reliable the prediction will be. Moreover, it is evident that these signs are not so clearly developed before puberty. The seven signs are related to the following features: (1) inclination of the condylar head, (2) curvature of the mandibular canal, (3) shape of the lower border of the mandible, (4) inclination of the symphysis, (5) interincisal angle, (6) interpremolar or intermolar angles, and (7) anterior lower face height.

These signs are illustrated by the two craniums shown in Fig. 6. In one of them there is a basal deep-bite, caused by extreme forward rotation, Type III,

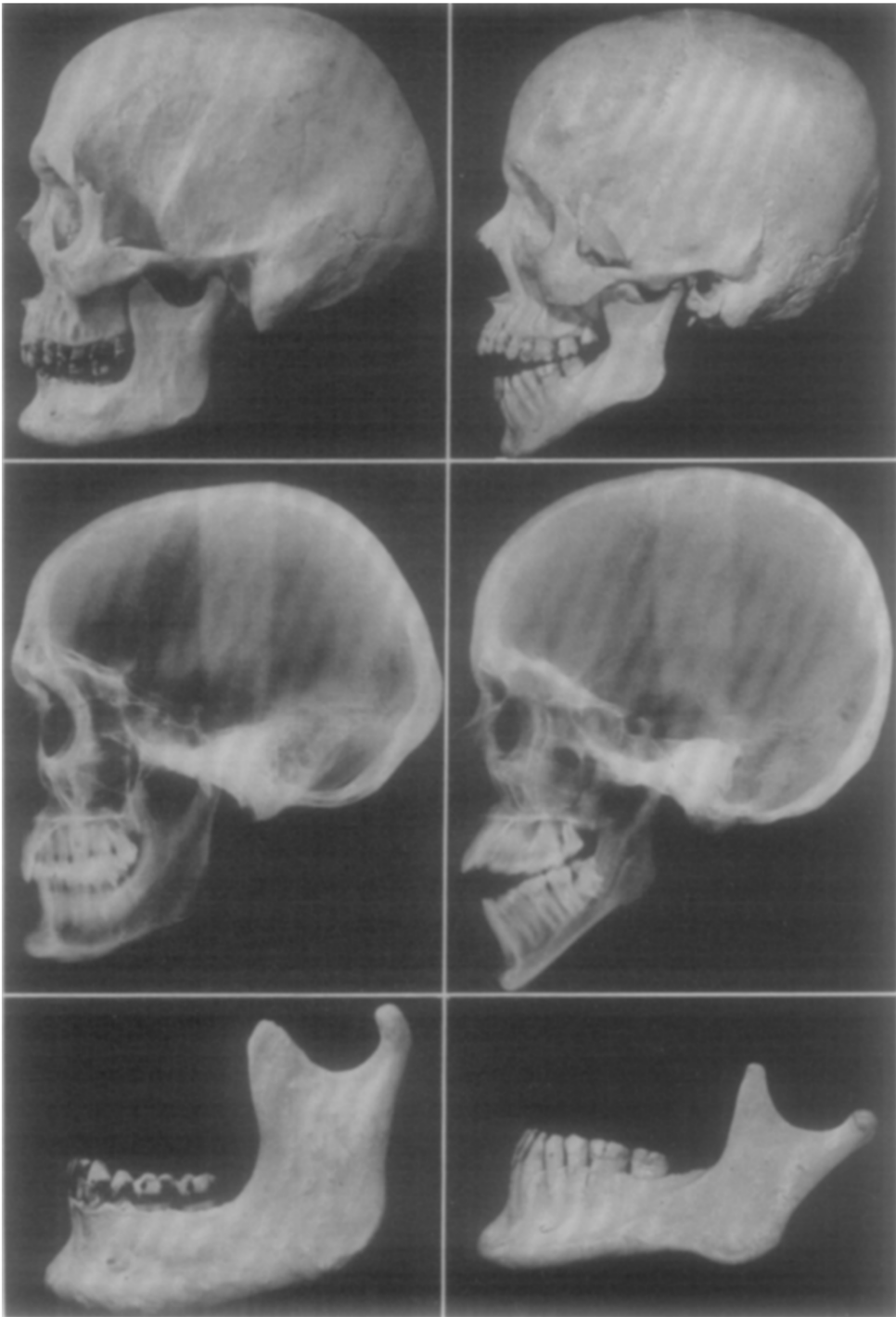


Fig. 6. Structural signs of mandibular growth rotation demonstrated in two craniums—one with basal deep-bite and one with basal open-bite.

in conjunction with growth at the condyles which is presumed to have been vertical. In the other there is a basal open-bite after what is presumed to have been a backward rotation of the mandible where the condylar growth must have been directed backward. (1) A forward or backward inclination of the condylar head is a characteristic sign, but it may not be easy to identify on the cephalometric radiogram, where part of the condyle is masked, as is seen in Fig. 6. (2) The curving of the mandibular canal may also be a clear sign. In the vertical type of condylar growth, the curvature of the canal tends to be greater than that of the mandibular contour, including the angle of the jaw, whereas in the sagittal type the opposite is generally the case. The canal may then be straight or, in pathologic cases, it may even curve in the opposite direction. (3) The shape of the lower border of the mandible is highly characteristic. In vertical condylar growth, the pronounced apposition below the symphysis and the anterior part of the mandible produces an anterior rounding, with a thick cortical layer, while the resorption at the angle produces a typical concavity. In sagittal growth, the anterior rounding is absent and the cortical layer is thin, while the lower contour at the jaw angle is convex. (4) The inclination of the symphysis is an important feature. In the vertical type of growth, the symphysis swings forward in the face and the chin is prominent, while in the sagittal type it is swung back, with a receding chin. The evaluation is complicated by the simultaneous remodeling of the alveolar process in the opposite direction, as is exemplified by the cranium with the open-bite. (5) The difference in the interincisor angle is evident, in spite of the compensatory tipping of the lower incisors. (6) The difference in the interpremolar and intermolar angles in the two growth types is also clear. (7) A compression or overdevelopment of the lower face is likewise typical. In the living subject there is a difference in the posture of the lips.

The inclination of the lower border of the mandible is not included among the signs, as it does not help in the evaluation, although this determination is included in practically all the systems of cephalometric analysis. Nor is the recording of the rest facial height a reliable guide.

Clinical aspects

Vertical malocclusion often receives less consideration than sagittal. No doubt, this is due in some measure to difficulty in detecting their relation to facial growth types.^{21, 24} In general, the more extreme the rotation of the mandible during growth, the greater the clinical problems that it presents. It is important to predict such rotations at an early stage, regardless of whether or not malocclusions have developed.

Extreme rotation, whether forward or backward, greatly influences the paths of eruption of the teeth. This has a bearing on the orthodontic tooth movement, and account must be taken of this in planning treatment. There is a serious risk of extreme migration after extractions, and secure anchorage is called for. Early loss of the deciduous molars likewise gives rise to marked migration. It is important to realize that crowding in the mandible results from both directions of growth rotation.

In the case of pronounced forward rotation, there is a major risk of deep-bite developing. This can be prevented by means of a stabilizing appliance, such as a bite plane, introduced before puberty. After treatment, such stabilization may be necessary until the growth of the jaws is completed. In our experience, it is advisable to delay extractions indicated on orthodontic grounds until the beginning of the puberal growth spurt, even when some other form of treatment has been introduced earlier.

In the case of backward rotation, opening of the bite is difficult to prevent. It has been our policy to postpone treatment until the puberal growth spurt is nearly over and to delay extractions until then.

It may be concluded that orthodontic procedures undoubtedly will improve with increasing knowledge of growth. Further perspectives lie in a better understanding of the timing of treatment to the individual rate of maturation.

Summary

A survey is presented of experience with the implant method in the study of facial growth, with particular emphasis on prediction of mandibular growth rotation. Three methods of prediction are discussed. (1) A *longitudinal* method, which consists of following the course of development by annual x-ray cephalograms, is shown to be of limited use for this purpose, as the remodeling process at the lower border of the mandible to a large extent masks the actual rotation. (2) A *metric* method, which aims at prediction based on a metric description of the facial morphology at a single stage of development, has so far not proved of value. (3) A *structural* method is described by which it may be possible to predict, from a single cephalogram, the course of rotation, where this feature is marked. This method is based on information gained from implant studies of the remodeling process of the mandible during growth.

REFERENCES

1. Björk, A.: The face in profile; an anthropological x-ray investigation on Swedish children and conscripts, *Svensk tandl. tidskr.* **40**: Supp. 5B, 1947.
2. Björk, A.: A discussion on the significance of growth changes in facial pattern and their relationship to changes in occlusion, *D. Record* **71**: 197-208, 1951.
3. Björk, A.: Variability and age changes in overjet and overbite, *AM. J. ORTHODONTICS* **39**: 779-801, 1953.
4. Björk, A.: Bite development and body build, *D. Record* **75**: 8-19, 1955.
5. Björk, A.: Cranial base development, *AM. J. ORTHODONTICS* **41**: 198-225, 1955.
6. Björk, A.: Facial growth in man, studied with the aid of metallic implants, *Acta odont. scandinav.* **13**: 9-34, 1955.
7. Björk, A.: Roentgen cephalometric growth analysis. In Pruzansky, S. (editor): *Congenital anomalies of the face and associated structures*, Springfield, Ill., 1961, Charles C Thomas Publisher, pp. 237-250.
8. Björk, A.: Facial growth in bilateral hypoplasia of the mandibular condyle: A radiographic, cephalometric study of a case, using metallic implants. In Kraus, B. S., and Riedel, R. A. (editors): *Vistas in orthodontics*, Philadelphia, 1962, Lea & Febiger, pp. 347-358.
9. Björk, A.: Cephalometric growth analysis by radiographic and implant technique, 16 mm. color film, 1962.
10. Björk, A.: Development of vertical malocclusions, 16 mm. color film, 1962.

11. Björk, A.: Variations in the growth pattern of the human mandible: Longitudinal radiographic study by the implant method, *J. D. Res.* **42**: 400-411, 1963.
12. Björk, A.: Käkarnas tillväxt och utveckling i relation till kraniet i dess helhet, *Nord. klin. odont., Köbenhavn*, 1965, Forlaget for Faglitteratur, Bind I: 1-44.
13. Björk, A.: Sutural growth of upper face, studied by the implant method, *Acta odont. scandinav.* **24**: 109-127, 1966.
14. Björk, A.: The use of metallic implants in the study of facial growth in children: Method and application, *Am. J. Phys. Anthrop.* **29**: 243-254, 1968.
15. Björk, A., and Helm, S.: Prediction of the age of maximum puberal growth in body height, *Angle Orthodontist* **37**: 134-143, 1967.
16. Björk, A., and Kuroda, T.: Congenital bilateral hypoplasia of the mandibular condyles associated with congenital bilateral palpebral ptosis, *AM. J. ORTHODONTICS* **54**: 584-600, 1968.
17. Björk, A., and Palling, M.: Adolescent age changes in sagittal jaw relation, alveolar prognathly and incisal inclination, *Acta odont. scandinav.* **12**: 201-232, 1954.
18. Hixon, E. H.: Prediction of facial growth, *Tr. European Orthodont. Soc.*, 1968.
19. Horowitz, S., and Hixon, E.: The nature of orthodontic diagnosis, *St. Louis*, 1966, The C. V. Mosby Company.
20. Kislign, E.: Cranial morphology in Down's syndrome. A comparative roentgen cephalometric study in adult males, *Thesis, København*, 1966, Ejnar Munksgaard.
21. Lager, H.: The individual growth pattern and stage of maturation as a basis for treatment of distal occlusion with overjet, *Tr. European Orthodont. Soc.*, pp. 137-145, 1967.
22. Lindegård, B.: Variations in human body build; a somatometric and x-ray cephalometric investigation on Scandinavian adults, *Acta psychiat. scandinav. Supp.* **86**, 1953.
23. Møller, E.: The chewing apparatus. An electromyographic study of the action of the muscles of mastication and its correlation to facial morphology, *Acta physiol. scandinav.* **69**: Supp. 280, 1966.
24. Skieller, V.: Cephalometric growth analysis in treatment of overbite, *Tr. European Orthodont. Soc.*, pp. 147-157, 1967.
25. Solow, B.: The pattern of craniofacial associations. A morphological and methodological correlation and factor analysis study on young male adults, *Acta odont. scandinav.* **24**: Supp. 46, 1966.
26. Tallgren, A.: Changes in adult face height, *Acta odont. scandinav.* **15**: Supp. 24, 1957.