

# *An evaluation of changes in mandibular anterior alignment from 10 to 20 years postretention*

**Robert M. Little, D.D.S., M.S.D., Ph.D.,\* Richard A. Riedel, D.D.S., M.S.D.,\*\* and Jon Årtun, D.D.S., M.S.D.\*\*\***

*Seattle, Wash., and Oslo, Norway*

Pretreatment, end of treatment, 10-year postretention, and 20-year postretention records of 31 four premolar extraction cases were assessed to evaluate stability and relapse of mandibular anterior alignment. Crowding continued to increase during the 10- to 20-year postretention phase but to a lesser degree than from the end of retention to 10 years postretention. Only 10% of the cases were judged to have clinically acceptable mandibular alignment at the last stage of diagnostic records. Cases responded in a diverse unpredictable manner with no apparent predictors of future success when considering pretreatment records or the treated results. (*Am J Orthod Dentofac Orthop* 1988;93:423-8.)

Of concern to patient and practitioner at the conclusion of active orthodontic treatment is the degree of anticipated stability. At what point is it safe to discontinue retainer use? At what age will there be no further change in anterior alignment? Once growth has been completed, can we assume that alignment will be maintained? The purpose of this study was to evaluate adolescent orthodontic treatment by evaluating postretention change at several decades of adult life and, if possible, to determine when and if relapse progression had stopped.

The focus of postretention studies has generally centered on the mandibular arch, interarch relationships, overbite, and overjet. The assumption is that alignment of the lower arch determines maxillary arch form and alignment, the lower arch serving as a template around which the upper arch develops and functions. Certainly, this is not always true, such as in some cleft palate cases that develop Angle Class III malocclusions, certain open bite cases, and unusual crossbite situations. Other than one published examination of maxillary relapse by Swanson, Riedel, and D'Anna,<sup>1</sup> only Rye<sup>2</sup> and Allred<sup>3</sup> have completed theses in our University of Washington graduate orthodontic program with consideration of maxillary dimensional changes postretention. (We hope to prepare that material for a future article.)

The present study is a sequel to a previous article in which long-term (minimum 10-year postretention) assessment of completed orthodontic cases was described in detail, the primary consideration being the mandibular arch.<sup>4</sup> Several conclusions were drawn.

1. Long-term alignment was variable and unpredictable.
2. No descriptive characteristics—such as Angle Class, length of retention, age of the initiation of treatment, or gender—nor measured variables—such as initial or end-of-active-treatment alignment, overbite, overjet, arch width, or arch length—were of value in predicting the long-term result.
3. Arch dimensions of width and length typically decreased after retention, whereas crowding increased. This occurred in spite of treatment maintenance of initial intercanine width, treatment expansion, or constriction.
4. Success at maintaining satisfactory mandibular anterior alignment is less than 30% with nearly 20% of the cases likely to show marked crowding many years after removal of retainers.

In contrast, studies from the University of Illinois Department of Orthodontics presented a more optimistic view of postretention results.<sup>5,6</sup> The difference may be inherent in the appraisal of the measurement technique, a method not comparable to that used in our research.

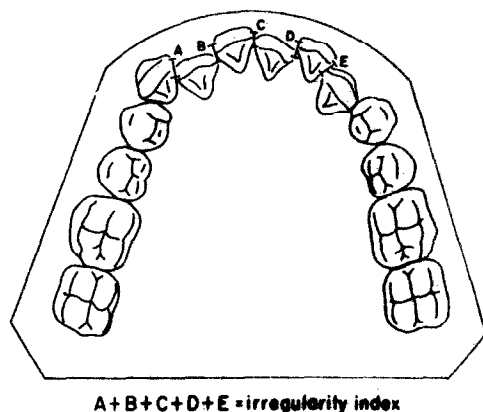
The present study was conducted to determine whether there is an age of final dental alignment stability. Orthodontists have been prone to assume that

From the Department of Orthodontics, University of Washington, and the University of Oslo.

\*Professor, Department of Orthodontics, University of Washington.

\*\*Professor, Department of Orthodontics, University of Washington.

\*\*\*Visiting Lecturer, Department of Orthodontics, University of Washington; Clinical Instructor, Department of Orthodontics, University of Oslo.



**Fig. 1.** Measurement technique. Irregularity Index defined as the summed displacement of adjacent anatomic contact points of the mandibular anterior teeth.

once growth has ceased the dentoocclusal changes will be minimal to negligible and therefore retention may no longer be necessary. It has been our subjective observation that changes in occlusion continue beyond a 5- and 10-year postretention period at varying rates and degrees, and these changes continue well beyond the point of growth cessation. Our goal was to assess the second decade (and beyond) of postretention follow-up.

## MATERIALS AND METHODS

The sample was limited to four premolar extraction cases that had undergone edgewise orthodontic treatment followed by retention and eventual removal of retainers. Thirty-one cases with complete records were collected from the files of the graduate orthodontic clinic at the University of Washington and from the offices of faculty. All cases had four sets of complete records: pretreatment, end of active treatment, a minimum of 10 years postretention, and a minimum of 20 years postretention (Table I). The quality of the treated or postretention result was not considered in the selection process; in fact, every effort was made to collect records without bias. All extractions had been accomplished in the permanent dentition and none of the cases had received a "sulcus slice" (circumferential supra-crestal fibrotomy) in an effort to avoid rotational change.

To quantify mandibular anterior irregularity, dial calipers were used to measure (at 0.01 mm) the displaced anatomic contact points. The summed displacement of the six lower anterior teeth, the Irregularity Index as described by Little,<sup>7</sup> was determined for each mandibular cast at each of the four time periods (Fig. 1). To reduce examiner bias, each cast was mea-

**Table I.** Sample characteristics

Age <sup>a</sup>	Median (yr-mo)	Range (yr-mo)
Pretreatment	13-2	9-6 to 16-3
Posttreatment	15-5	12-1 to 18-8
10 years postretention	30-4	24-8 to 40-11
20 years postretention	43-3	37-3 to 50-0
Retention period	2-0	0-6 to 5-4

sured in random order with similar measurement errors as in previous research (0.10 to 0.30 mm).

## RESULTS

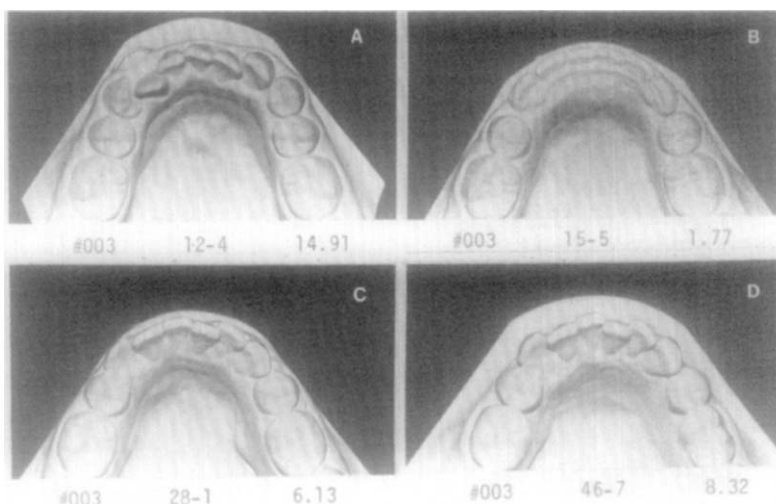
The average and range of irregularity observed are shown in Table II. Considerable pretreatment variation was noted, the average score being more than 7 mm with the range varying markedly from 2 to 18 mm. The end of treatment result demonstrated uniformly acceptable alignment with minimal variation. At the 10-year postretention stage, the mean irregularity of +5 mm was not acceptable, but there was a considerable range of 2 to 10 mm. From 10 to 20 years postretention, all cases deteriorated, some more than others. The average irregularity increased by nearly 1 mm; the range also moved to higher scores.

Most changes from 10 to 20 years postretention were slight—less than 1 mm of increased irregularity; however, a few cases demonstrated an increase of 2 to 3 mm. At the 20-year postretention stage, only three cases of 31 had irregularity considered clinically acceptable or minimal (3.5 mm); ten cases were severely crowded (6.5 mm). In our previous research on 10-year postretention cases,<sup>4</sup> approximately 30% were considered clinically acceptable at the postretention stage; in this sample only 10% could be considered satisfactory. Overbite and overjet showed minimal change from 10 to 20 years postretention with no consistent pattern noted.

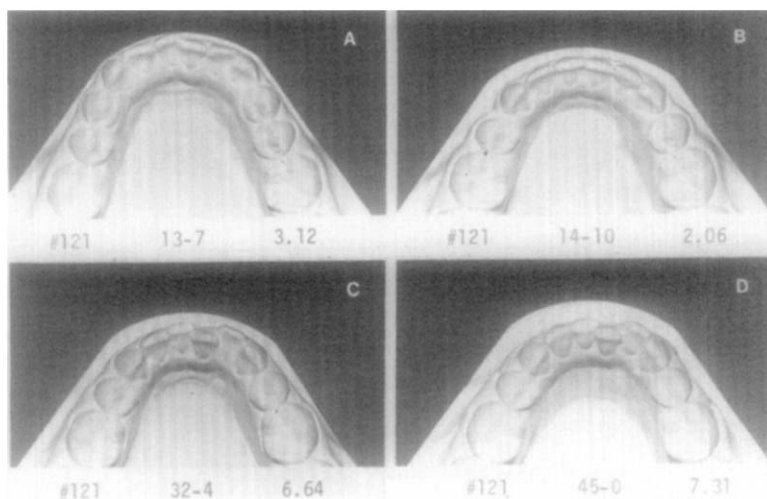
Several typical cases are used to illustrate the variation in response.

*Case 003 (Fig. 2).* The initial irregularity was reduced during treatment, but by age 28 (10 years postretention), the Irregularity Index had increased to more than 6 mm and during the next 18 years, the crowding score further increased to more than 8 mm. Although not identical to the initial incisor pattern, the displaced teeth at age 46 years (28 years postretention) do resemble the original with the exception of the right central incisor, which deviated into a lingual malposition. Note the increased incisal wear and the overcontoured restorations.

*Case 121 (Fig. 3).* The original mild irregularity was resolved by age 14, but considerable crowding was noted by



**Figs. 2 through 7.** Casts at pretreatment (A), posttreatment (B), 10 years postretention (C), and 20 years postretention (D). Case number, age in years and months, and Irregularity Index are shown below.



**Fig. 3.** For legend, see Fig. 2.

**Table II.** Mandibular anterior malalignment values

<i>Irregularity Index</i>	<i>Mean (mm)</i>	<i>Range (mm)</i>
Pretreatment	7.41	1.88 to 18.08
Posttreatment	1.66	0.25 to 3.49
10 years postretention	5.25	1.96 to 10.14
20 years postretention	6.02	2.38 to 11.48

age 32 (15 years postretention). The case showed only slight increase of crowding during the next 13-year period and by age 45 (28 years postretention) demonstrated a pattern dissimilar to and more crowded than the pretreatment original condition. Most of the crowding involved the lingual position

of the right central incisor. The rotations after treatment do not always mimic the original condition—that is, the lateral incisors.

*Case 139 (Fig. 4).* Following serial extraction and routine edgewise treatment, the case was completed by age 15. By

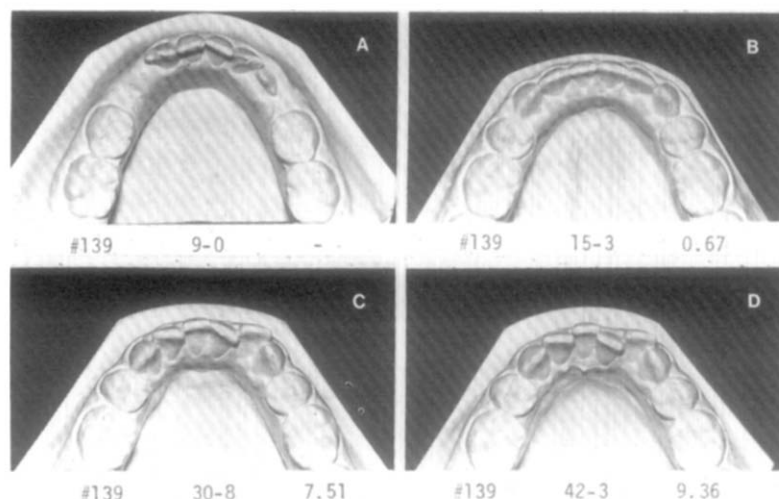


Fig. 4. For legend, see Fig. 2.

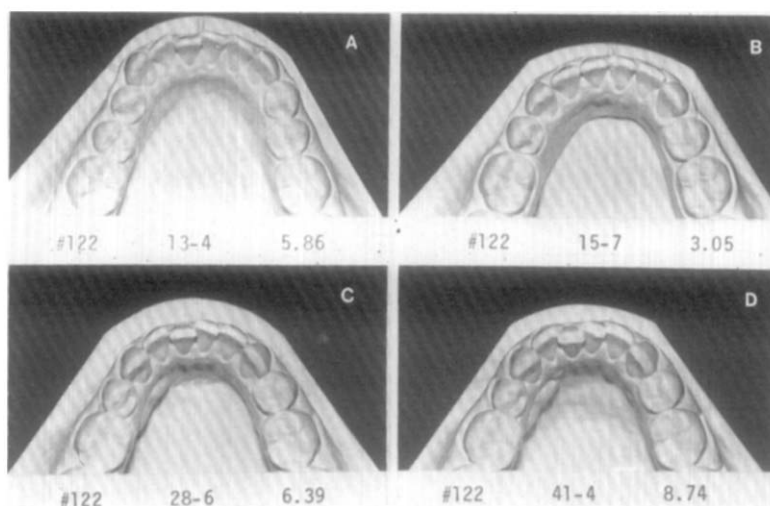


Fig. 5. For legend, see Fig. 2.

age 30 (15 years postretention), considerable crowding was noted in a pattern similar to the original but more crowded. During the next 12 years, the crowding worsened; the contact points becoming more displaced by age 42 (27 years postretention). This case exhibited one of the larger 10- to 20-year postretention changes and is particularly interesting given the initial minimal irregularity.

*Case 122 (Fig. 5).* Note the similarity in anterior malalignment comparing the pretreatment condition to age 28 (10 years postretention) and age 41 (23 years postretention) records. Displaced contacts continued to worsen and incisor abrasion increased during the fourth and fifth decades of life.

*Case 202 (Fig. 6).* Although the pretreatment malalignment is substantial, by age 30 (14 years postretention) there was only a slight change from the end of active treatment record—primarily one incisor showing rotation. By age 39 (24 years postretention), the crowding pattern had worsened.

*Case 106 (Fig. 7).* Considerable crowding is evident by age 28 (14 years postretention) with continued crowding by age 39 (24 years postretention). In spite of near perfect initial anterior alignment, this case deteriorated to a marked extent, defying our usual criterion of prediction and prognosis. The initial deep overbite was corrected and did not relapse, the overbite apparently not playing a role in the anterior malalignment noted.

#### DISCUSSION AND CLINICAL IMPLICATIONS

Treatment techniques in vogue during the care of these cases involved retraction or maintenance of lower anterior position and angulation. Cephalometric assessment of the sample showed this to be true for 29 of the 31 cases. Both of the exceptions had extractions followed by physiologic drift, considerable crowding

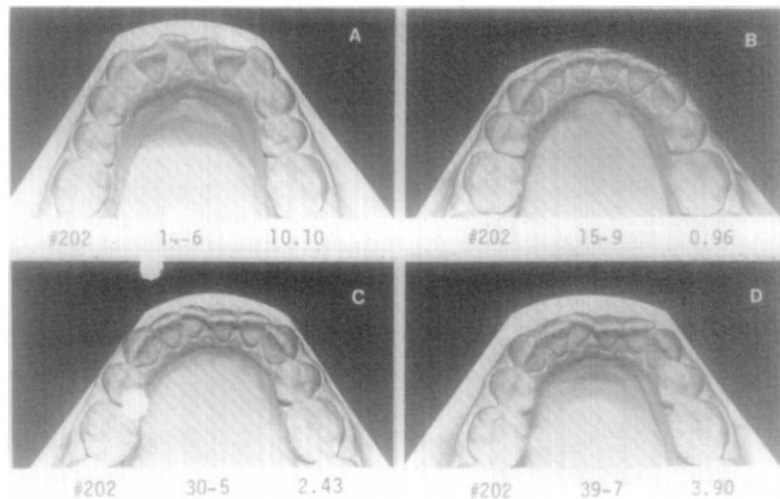


Fig. 6. For legend, see Fig. 2.

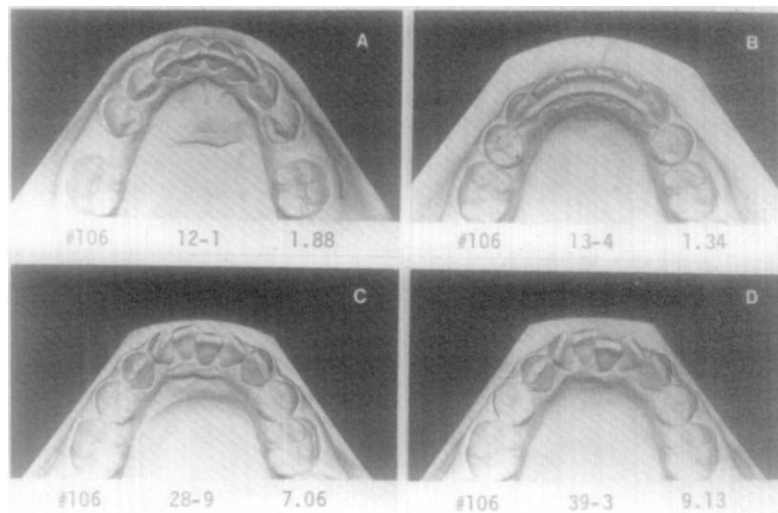


Fig. 7. For legend, see Fig. 2.

before appliance placement, and some incisor flaring in spite of an active effort to minimize protrusion. The sample illustrates cases well handled and directed toward upright, not procumbent, incisor position as a treatment goal.

None of the cases in this sample received a circumferential supracrestal fiberotomy (CSF) to avoid rotational change, all having been treated before the "sulcus slice" procedure came into vogue. Boese<sup>8,9</sup> has advocated a combination of CSF and incisor narrowing (reproximation), demonstrating success at maintaining the treated correction. In our limited study of fiberotomy and rotational relapse 2 to 9 years postretention, Rye<sup>2</sup> found 23% rotational relapse of a fiberotomized sample compared with 39% relapse for the nonsurgical group.

In spite of not having a "sulcus slice," 61% of rotated teeth did not rerotate. There may be an improvement by such means but our preliminary results show that rotation often can occur in spite of CSF procedures and conversely that rotations may not recur even though CSF was not done.

The process of arch constriction that accompanies anterior crowding appears to continue well after the cessation of active growth. During the 20- to 30-year age span, considerable change occurs routinely. From age 30 to 40 and beyond, the process continues, but usually at a lessened rate or degree. There is marked variation among patients, a few reaching a point of apparent stability by the late teenage years, but most showing active and significant changes for years and

even decades after orthodontic therapy. From 10 to 20 years postretention, most crowding increases are modest, but the degree of malalignment for an individual case is not predictable. One factor that is consistently predictable is the continuing decrease in mandibular arch length that occurs with time following removal of retainers.

The only way to *ensure* continued satisfactory alignment posttreatment probably is by use of fixed or removable retention for life. The number of needed hours per day, week, or month will vary from patient to patient and with use of removable appliances the amount of wear will be out of the control of the orthodontist. Presently, the effects of prolonged retention have not been evaluated (except in isolated instances), particularly the physiologic and pathologic consequences relative to the health of teeth, soft tissue, and bone. Such future study is warranted, given the likely need for prolonged retention as a normal treatment measure.

Patients and parents of our young patients should be apprised beforehand of the liability for posttreatment change. They must understand clearly our limitations and their roles in the maintenance of the treated results. The orthodontist should not assume that stability will occur, but should assume instability will likely be the pattern and, with such a posture, can plan against and prevent undesirable change.

## REFERENCES

1. Swanson W, Riedel R, D'Anna J. Postretention study: incidence and stability of rotated teeth in humans. *Angle Orthod* 1975; 45:198-203.
2. Rye W. A long term assessment of the clinical efficacy of the circumferential supracrestal fiberotomy [Master's thesis]. Seattle: University of Washington School of Dentistry, 1983.
3. Allred K. Stability and relapse of maxillary anterior alignment: a postretention study of premolar extraction cases treated by traditional edgewise orthodontics [Master's thesis]. Seattle. University of Washington School of Dentistry, 1986.
4. Little R, Wallen T, Riedel R. Stability and relapse of mandibular anterior alignment—first premolar extraction cases treated by traditional edgewise orthodontics. *AM J ORTHOD* 1981;80:349-65.
5. Sadowsky C, Sakols E. Long-term assessment of orthodontic relapse. *AM J ORTHOD* 1982;82:456-63.
6. Uhde M, Sadowsky C, Be Gole E. Long-term stability of dental relationships after orthodontic treatment. *Angle Orthod* 1983;53: 240-52.
7. Little R. The Irregularity Index: a quantitative score of mandibular anterior alignment. *AM J ORTHOD* 1975;68:554-63.
8. Boese LR. Fiberotomy and reproximation without lower retention, nine years in retrospect. Part I. *Angle Orthod* 1980;50:88-97.
9. Boese LR. Fiberotomy and reproximation without lower retention, nine years in retrospect. Part II. *Angle Orthod* 1980;50:169-78.

*Reprint requests to.*

Dr. Robert M. Little  
University of Washington School of Dentistry  
Department of Orthodontics, SM-46  
Seattle, WA 98195

### BOUND VOLUMES AVAILABLE TO SUBSCRIBERS

Bound volumes of the AMERICAN JOURNAL OF ORTHODONTICS AND DENTOFACIAL ORTHOPEDICS are available to subscribers (only) for the 1988 issues from the Publisher, at a cost of \$42.00 (\$52.00 international) for Vol. 93 (January-June) and Vol. 94 (July-December). Shipping charges are included. Each bound volume contains a subject and author index and all advertising is removed. Copies are shipped within 60 days after publication of the last issue in the volume. The binding is durable buckram with the journal name, volume number, and year stamped in gold on the spine. *Payment must accompany all orders.* Contact The C. V. Mosby Company, Circulation Department, 11830 Westline Industrial Drive, St. Louis, Missouri 63146, USA; phone (800) 325-4177, ext. 351.

**Subscriptions must be in force to qualify. Bound volumes are not available in place of a regular Journal subscription.**