

The importance of incisor positioning in the esthetic smile: The smile arc

David M. Sarver, DMD, MS

Birmingham, Ala

The *smile arc* is defined as the relationship of the curvature of the incisal edges of the maxillary incisors and canines to the curvature of the lower lip in the posed smile. The ideal smile arc has the maxillary incisal edge curvature parallel to the curvature of the lower lip. Evaluation of anterior smile esthetics must include both static and dynamic evaluations of profile, frontal, and 45° views to optimize both dental and facial appearance in orthodontic planning and treatment. This article presents the concept of the smile arc and how it relates to orthodontics—from the recognition of its importance, to its impact on orthodontic treatment planning, to how procedures and mechanics are adapted to optimize the appearance of the smile. Three cases are used to illustrate how treatment is directed, emphasizing how facial and smile goal setting go hand in hand. (Am J Orthod Dentofacial Orthop 2001;120:98-111)

The subject of the smile and facial animation as they relate to communication and expression of emotion is, and should be, of great interest to orthodontists. Although the English language is replete with words that conjure up images of specific types of smiles—*insipid*, *wry*, *sardonic*, *ironic*, *inscrutable*, *infectious*, *warm*, and *enigmatic*—these descriptions are entirely subjective. An attractive smile helps win elections, and a beautiful smile sells products for companies whose subliminal message in advertising is “look better, feel younger.” But even a well-treated orthodontic case in which the plaster casts meet every criterion of the American Board of Orthodontics for successful treatment may not produce an esthetic smile.

Few objective criteria exist for assessing attributes of the smile, establishing lip-teeth relationships as objectives of treatment, or measuring the soft tissue outcomes of treatment. It would be nice to have some sort of a tool to quantitatively assess beauty but, currently, one does not exist—and it probably never will. As a result, an eye for beauty is an important attribute for an orthodontist.

When a patient looks in the mirror, the smile he or she sees is framed by what Lavater,¹ more than 200 years ago, called the *lip curtain* and what is currently called the *soft tissue drape*. Smiles can be either *posed* or *spontaneous*. Peck and Peck² classified smiles as

stages I and II, and Ackerman et al³ designated the stage I smile as the posed smile and stage II as the unposed (spontaneous) smile. The posed smile (Fig 1, A) is voluntary and need not be elicited or accompanied by emotion. A posed smile is static in the sense that it can be sustained. The lip animation is fairly reproducible, similar to the smile that may be rehearsed for photographs or school pictures.^{4,5}

The unposed smile (Fig 1, B) is involuntary and is induced by joy or mirth. It is dynamic in the sense that it bursts forth but is not sustained. An unposed smile is natural in that it expresses authentic human emotion. Lip elevation in the unposed smile is often more animated, as seen in the laughing smile, for example.

In orthodontic smile analysis, we usually evaluate the posed smile on the basis of 2 major characteristics: the amount of incisor and gingival display and the transverse dimension of the smile.

Most orthodontists and dentists prefer that the elevation of the lip for the posed smile stop at the gingival margins of the maxillary incisors, as depicted in Figure 1, A. Some amount of gingival display is certainly acceptable and, in many cases, is even esthetic and youthful appearing (Fig 2). Conversely, a complete lack of gingival display (defined in terms of the percentage of incisor show on smile) is not as attractive as complete tooth display or even some gingival display.^{6,7} Males, as a group, show less of the maxillary incisors and more of the mandibular incisors at rest and on smile than do females.⁸ It is a characteristic of aging to show less of the maxillary incisors at rest and on smile, so that, to a degree, more tooth display is considered a more youthful smile.

The transverse dimension of the smile was first introduced in the prosthodontic literature by Frush and

Adjunct Professor, University of North Carolina, Department of Orthodontics, and in Private Practice, Vestavia Hills, Alabama.

Reprint requests to: David M. Sarver, 1705 Vestavia Parkway, Vestavia Hills, AL 35216; e-mail, sarverd@aol.com.

Submitted, November 2000; revised and accepted, January 2001.

Copyright © 2001 by the American Association of Orthodontists.

0889-5406/2001/\$35.00 + 0 8/1/114301

doi:10.1067/mod.2001.114301

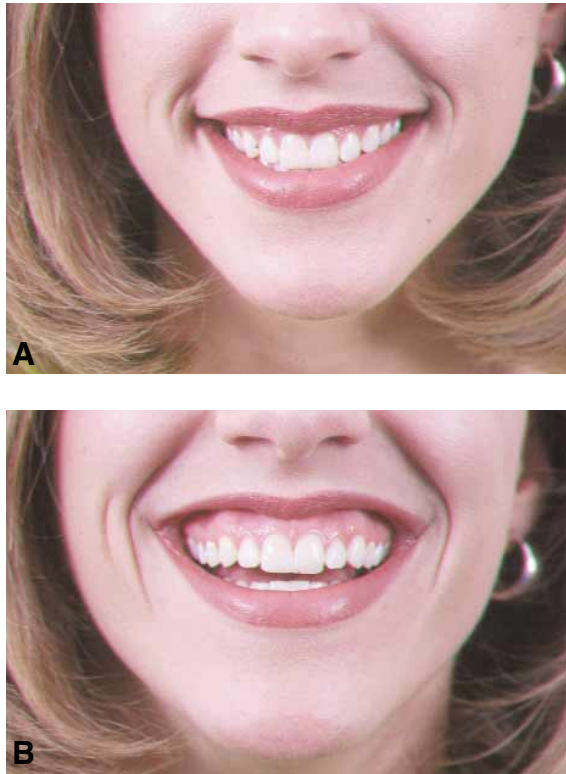


Fig 1. A, Posed smile is voluntary and may produce fairly reproducible lip animation; **B,** unposed smile is involuntary and spontaneous, often characterized by more lip elevation than in posed smile.

Fisher.⁹ This smile characteristic is referred to in terms of *broadness to the smile* and the presence and the amount of *buccal corridors* (more commonly referred to by orthodontists as *negative space*). It is well documented in the prosthodontic literature that one characteristic of an unrealistic or contrived smile—a “denture smile”—is the lack of buccal corridors. *Anything can be overdone*. Again, the orthodontist’s eye for beauty is an important factor in creating appropriately sized buccal corridors. This smile feature has been thought of primarily in terms of maxillary width, but there is evidence that the buccal corridors are also heavily influenced by the anteroposterior position of the maxilla relative to the lip drape.^{10,11}

A characteristic of the esthetic smile that has not been as well recognized is the relationship of the curvature of the maxillary anterior teeth (smile arc) in the esthetic smile. The term *smile arc* has a number of definitions depending on whether one is reading literature from prosthodontics, orthodontics, or cosmetic dentistry. In his cosmetic dentistry text, Goldstein¹² describes the “older smile,” in which the incisal edges



Fig 2. Some gingival display on smile is esthetically appealing because of the youthfulness of incisor show.

appear straight across the smile, and contrasts it with the “youthful smile” in which the front teeth are longer and create a line that comes slightly downward in the middle of the smile, traveling superiorly to the corners. Frush and Fisher⁹ proposed that there should be harmony between the curvature of the incisal edges of the maxillary anterior teeth and the curvature of the upper border of the lower lip; this is referred to as the smile arc.

Definition of the smile arc

The smile arc should be defined as the relationship of the curvature of the incisal edges of the maxillary incisors and canines to the curvature of the lower lip in the posed smile. The ideal smile arc has the maxillary incisal edge curvature parallel to the curvature of the lower lip upon smile; the term *consonant* is used to describe this parallel relationship (Fig 3, A). A *nonconsonant*, or flat, smile arc is characterized by the maxillary incisal curvature being flatter than the curvature of the lower lip on smile, as shown in Figure 3, B.

Conceptual evolution

The importance of the smile arc, as an esthetic concept, has probably not been fully appreciated by ortho-

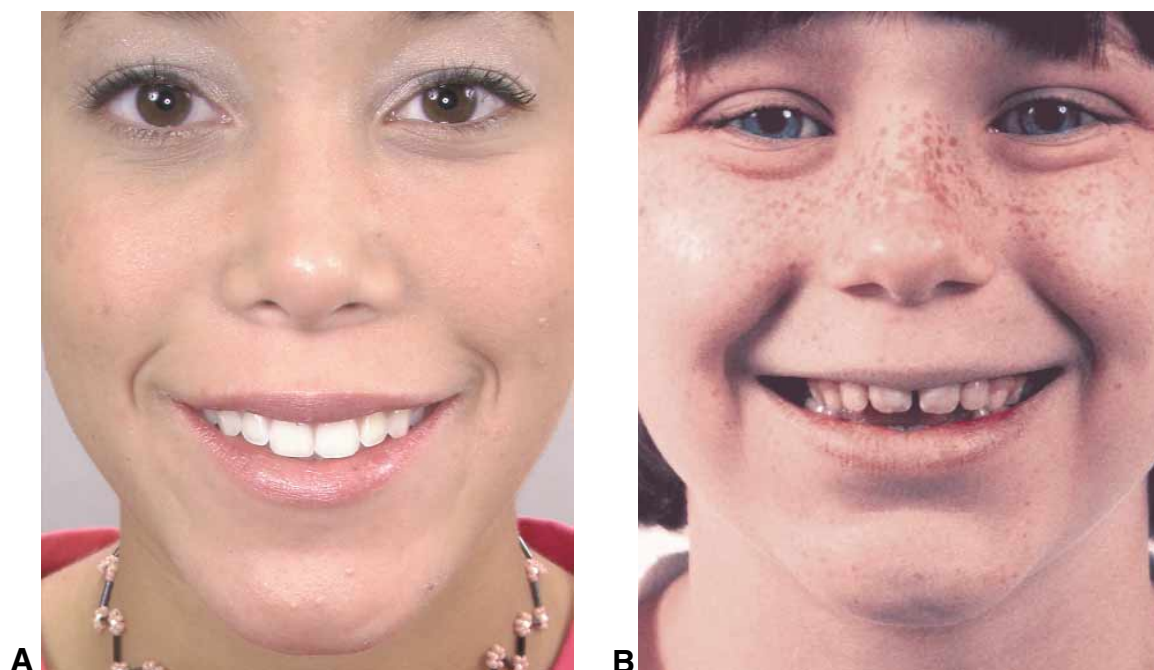

Fig 3. A, Ideal smile arc is characterized by consonant relationship of arc formed by maxillary teeth and lower lip on smile; **B,** nonconsonant, or flat, smile arc is characterized by maxillary incisal arc line that is flatter than curvature of lower lip on smile.

dentists. Hulse⁴ assessed standardized photographs of 40 subjects, 20 treated orthodontically and 20 considered to have normal occlusion. He noted that the curvature of the incisal edges of the maxillary anterior teeth was flatter in those who were treated orthodontically. A panel judged the smiles with flatter arcs as being less attractive, confirming the hypothesis of Frush and Fisher.⁹ Zachrisson¹³ has made similar observations that some treated smiles are less esthetic.

In a recent study, Ackerman et al³ evaluated the smile arc in both treated and untreated patients in their own practice. Almost 40% of the treated patients showed a discernible change in the smile arc; flattening of the smile arc occurred in 32%. In the untreated group, 13% had a change in the smile arc, and flattening of the arc occurred in only 5%. They noted no gender differences in the smile characteristics when the treated and untreated groups were compared.³

Smile arc flattening during orthodontic treatment can occur in several ways. Normal orthodontic alignment of the maxillary and mandibular arches may result in a loss of the curvature of the maxillary incisors relative to the lower lip curvature. In case evaluation, it is important to assess and visualize the incisor-smile arc relationships and place brackets so as to extrude the maxillary incisors in flat smiles and to maintain the

smile arc where it is appropriate. A set formula for bracket placement based on tooth measurements, as is often taught in orthodontic courses and programs, is not appropriate for maximum esthetics. For example, if all patients routinely have their maxillary central incisors placed 4.5 mm above the incisal edge, their lateral incisors at 4 mm, and their canines at 5 mm, without the clinician taking into account the relationship of the incisal edges to the lower lip curvature in each individual case, the positioning may or may not fit the esthetic criteria required. Just as patients get individualized treatment plans, they also should have individualized designs for appliance placement.

Bracket placement may unwittingly lead to superior repositioning of the incisal edges relative to the posterior buccal segment heights. For example, with our emphasis on the goal of attaining canine guidance, it is possible that we are creating relative intrusion of the maxillary incisors while extruding the maxillary canines. The 14-year-old patient in Figure 4, A, has a nonconsonant smile arc with 80% of the maxillary incisors displayed on smile. While canine guidance has been emphasized in this case, it may be at the expense of the appearance of the smile. Another possibility arises when lower bracket placement in the same patient is evaluated (Fig 4, B). Note that the mandibu-

lar incisor brackets were placed very close to the gingival margins, probably in an effort to avoid occlusal interferences that might cause unwanted bracket loss. Unfortunately, this resulted in extrusion of the mandibular incisors, and the maxillary incisors had to be compensated vertically to open the bite, which also contributed to flattening of the smile arc.

In patients in whom excessive gingival display on smile is noted, and for whom one of the treatment objectives is to reduce the gumminess of the smile, maxillary incisor intrusion may improve the gingival display on smile. However, if the smile arc relationship has not been noted and evaluated, unwanted flattening of the smile arc may result. Maxillary intrusion arches or maxillary archwires with accentuated curve could result in a flattening of the smile arc.

The subject's inherent growth pattern may also be at fault. The studies of smile arc flattening have shown that, while treated patients did have a higher rate of smile arc flattening, 5% of the untreated population also experienced smile arc flattening. More vertical growth in the posterior maxilla than in the anterior maxilla could result in a changed relationship between the occlusal plane and the curvature of the lower lip upon smile. In this type of patient, high-pull headgear keeps the maxillary posterior teeth superior to the incisors and is therefore an aid in maintaining or improving the smile arc.

It is also possible that growth in the brachyfacial pattern (low mandibular plane angle and a tendency for parallelism of the sella-nasion line, palatal plane, and occlusal plane) may lead to a flat smile arc. Patients with this skeletal pattern might, theoretically, have a tendency for the anterior maxilla to lack the clockwise tilt needed for an ideal smile arc; in some cases it might even exhibit a counterclockwise tilt that results in a flat smile arc. Whether this is fact, however, is yet to be proven.

Habits may also be an etiologic factor. The reduction in anterior vertical dentoalveolar development secondary to thumb sucking is the most obvious example.

CASE ILLUSTRATIONS

Case 1

Treatment planning for this patient was a challenge because of discordant esthetic and functional goals. This demonstrates how problem-oriented treatment planning helps us identify a path to the attainment of our desired treatment goals. In this patient, the smile arc was an important consideration in planning treatment.

At age 11, the patient's chief complaint was the diastema between the maxillary incisors. The parents,

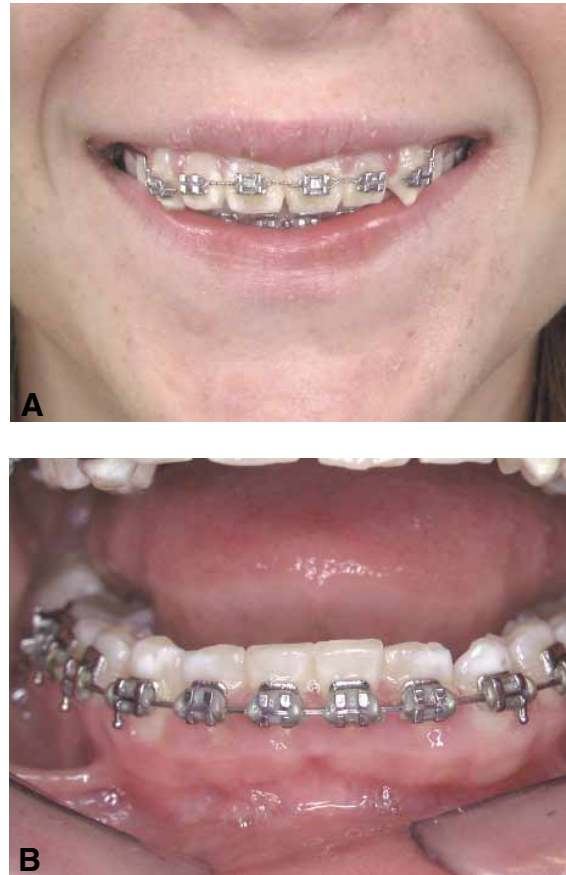

Fig 4. A, Bracket placement to emphasize canine guidance may be at the expense of appearance of the smile by relatively intruding maxillary incisors, resulting in flat smile arc; **B,** maxillary incisor intrusion is required to open the bite, resulting in flattening of smile arc.

however, were concerned about the mandibular deficiency and its effect on her facial appearance and were committed to a treatment plan directed at facial improvement in addition to occlusal correction (Fig 5, A-C).

Data from systematic analysis of the patient, beginning appropriately with an examination of facial proportions, was summarized.^{6,14}

Profile. Relative to the upper face, the maxilla appeared to be moderately procumbent, but the most remarkable aspects of the patient's profile included an obtuse chin-neck angle, a short lower facial height with short chin height, and a deep labiomental sulcus with eversion of the lower lip (Fig 5, A).

Frontal at rest. The lower facial height was short, with the upper lip and chin height ratio approximating 50:50, versus the ideal 33:66 ratio. The lower facial height presented a problem in reaching occlusal goals,

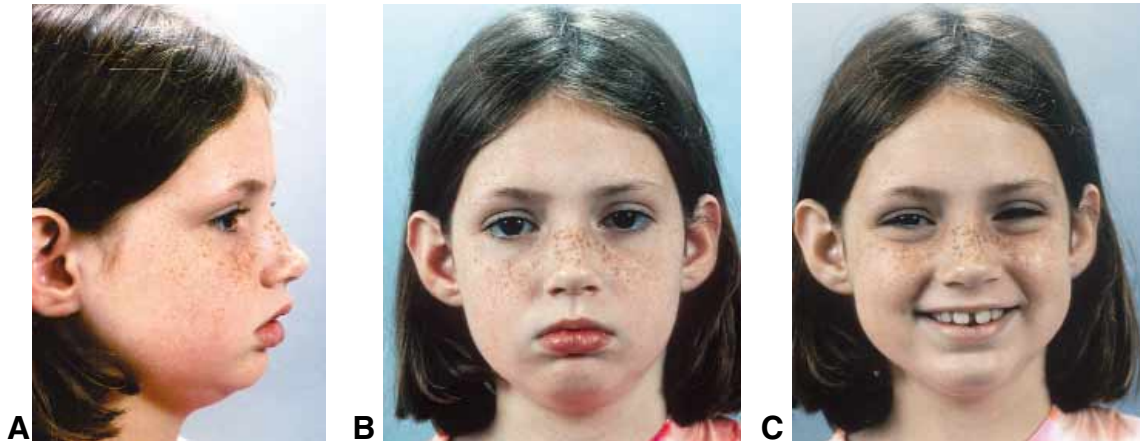


Fig 5. **A**, This patient's profile was characterized by deficient mandibular height, in both horizontal projection and vertical height; **B**, patient had short lower facial height with everted lower lip; **C**, approximately 80% of maxillary incisor showed on smile; with further maturation and aging, this amount of tooth show is expected to decrease.

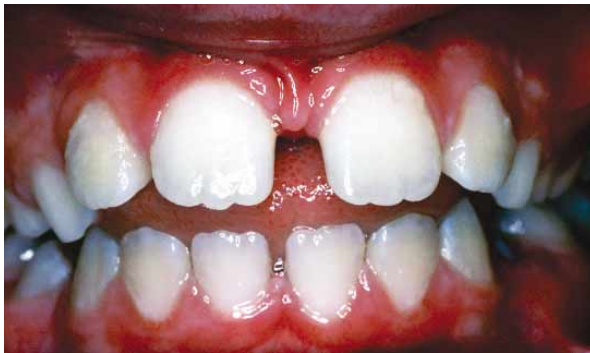

Fig 6. Anterior open bite was present, an occlusal relationship not frequently associated with short-faced patients.

as will be seen later in this analysis, because the patient had an open bite. She also had an everted lower lip and a deep labiomentental sulcus (Fig 5, B).

Frontal on smile. Only 80% of the maxillary incisor was exposed on smile, and with further maturation and aging, this amount was expected to decrease.⁸ Therefore, the lack of incisor show was considered both an initial esthetic problem and a long-term problem because it was expected to worsen with further growth and maturation. Also present was the large maxillary midline diastema (Fig 5, C).

Dental relationships. The patient had an anterior open bite with bilateral Class II molar relationships (Fig 6). The maxillary incisors were flared and a large maxillary midline diastema present. Spacing of approximately 5 mm was also present in the mandibular arch.

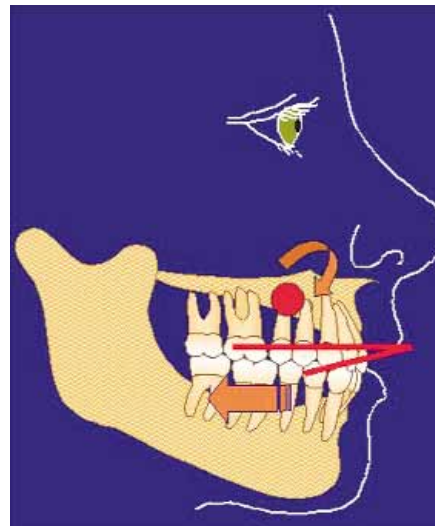


Fig 7. Growth modification through use of cervical headgear was chosen. Outer bow was shortened and placed inferiorly in an effort to have desirable effects of cervical headgear (maxillary retardation, downward vector to increase lower facial height) in addition to producing rotational effect on palatal plane to continue increase in incisor show and continue bite closure.

The treatment goals for this patient were to correct both the esthetic problems and the Class II open bite malocclusion. The esthetic problems in this case, as summarized from the facial characteristics and the incisor-smile relationship, were:

1. Marked mandibular deficiency noted on profile, with concomitant obtuse chin-neck angle;

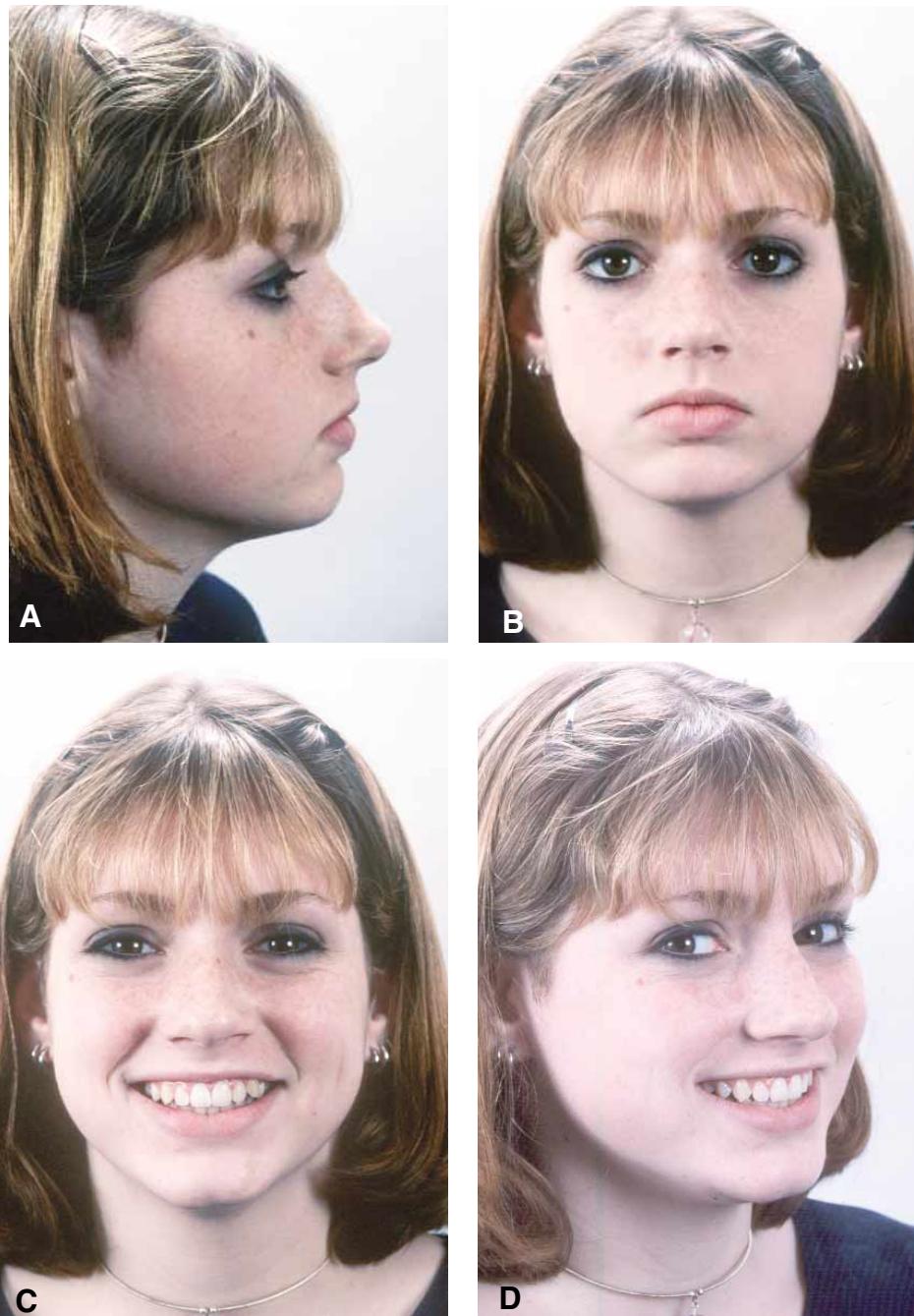

Fig 8. **A**, Final profile reflected vast improvement of lower facial projection and increase in facial height; **B**, final frontal picture demonstrates significant increase in lower facial height; **C**, on smile, all maxillary teeth show, with beautiful smile vertically, as well as ideal smile arc relationship; **D**, 45° view clearly shows excellent smile arc relationship as well as improved submental and submandibular soft tissue.

2. Short lower facial height, a problem for both profile and frontal relationships;
3. Maxillary anterior dental spacing;
4. Lack of incisor show at rest and on smile;
5. Flat smile arc.

The major treatment challenge in this case was that several changes to correct the open bite and the Class II relationships would also tend to exacerbate esthetic problems. We very rarely see an anterior open bite in a short-faced patient, and the orthopedic forces used to

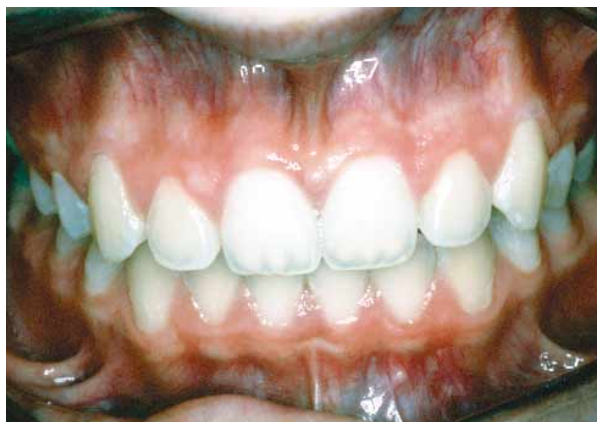

Fig 9. Final frontal dental pictures reflect successful bite closure.

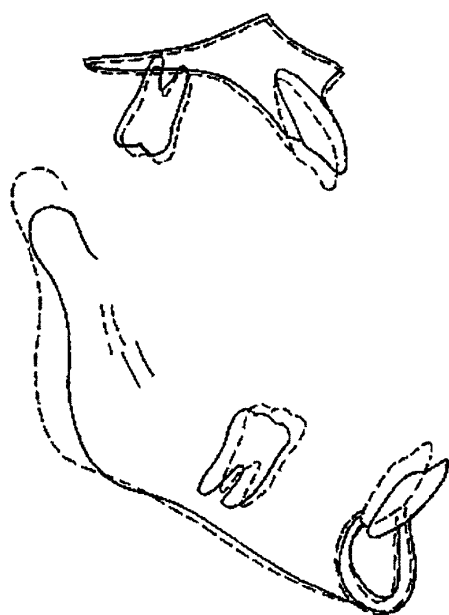


Fig 10. Superimposition on palatal plane demonstrates uprighting of maxillary anterior teeth resulting in retraction and lengthening of maxillary incisors relative to upper lip. This movement improved smile by increasing tooth display. Mandibular superimposition demonstrates uprighting and retraction of mandibular incisors, resulting in bite deepening and increased overjet.

reduce vertical growth and close the open bite would work against the goal of increasing lower face height.

Extrusion of the maxillary anterior teeth to increase the amount of tooth exposure on smile was both desirable and possible because the teeth were markedly flared and space was present. Space closure by upright-

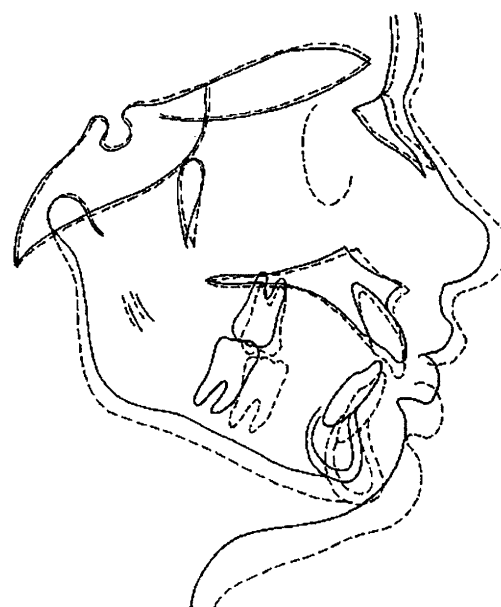


Fig 11. Overall superimposition reflects that rotation of palatal plane was favorably clockwise and amount of mandibular growth was significant, resulting in remarkable improvement in skeletal relationships.

ing the incisors through retraction on round wire (to allow the crown to rotate inferiorly) would elongate the crowns of the teeth, which would accomplish the functional goal of closing the bite and increasing the amount of tooth show at rest and on smile.⁶ Extrusion of the maxillary incisors also offered the advantage of steepening the smile arc to be more consonant with the lower lip. Extrusion of the maxillary incisors would allow more tooth to show on smile and would close the bite but would not increase lower facial height.

Growth modification also required careful choices. The goal was to bring the mandible relatively forward and increase the lower facial height to improve overall vertical facial proportionality and the deep labiomental sulcus. The everted lower lip was due to a combination of soft tissue redundancy created by the decreased vertical dimension of the face and excessive overjet. However, an increase in the lower facial height would work against closing the bite. Thus, growth modification with cervical headgear was selected to place force on the maxilla; however, the outer bow was shortened and placed inferiorly (Fig 7). The use of cervical headgear in a patient with an open bite is unusual, but full appliance engagement of the entire maxillary arch would theoretically result in clockwise rotation of the palatal plane, which would also close the bite and extrude the anterior segment to increase incisor show.



Fig 12. This 35-year-old female had a chief complaint of dental crowding. Frontal facial proportions at rest were normal, and smile line was characterized by ideal incisor curvature to lower lip line.

Treatment was initiated during the prepubertal growth phase at age 11 with a maxillary fixed appliance and cervical headgear; additional appliances were placed as the remaining permanent teeth erupted. Once .016-in archwires were attained (in a .018-in appliance), elastic chain was used to close the maxillary diastema, and the remainder of treatment was directed toward managing the maxillary rotation and bite closure. After approximately 30 months of treatment, the patient's profile (Fig 8, A) was dramatically improved with improved mandibular projection, an increase in the lower facial height, and a significant change in the chin-neck angle. An improvement in the cervicomental angle should be expected with increased mandibular projection, but the soft tissue changes with the growth spurt were also a great addition.¹⁵ The resting frontal relationship (Fig 8, B) was characterized by an increase in the lower facial height. The smile was greatly improved with much more incisor show on smile (Fig 8, C) and a consonant smile arc. The 45° view (Fig 8, D) shows the smile and the lower facial changes attained. The final dental relationships were greatly improved (Fig 9), with some mild unilateral Class II asymmetry remaining.

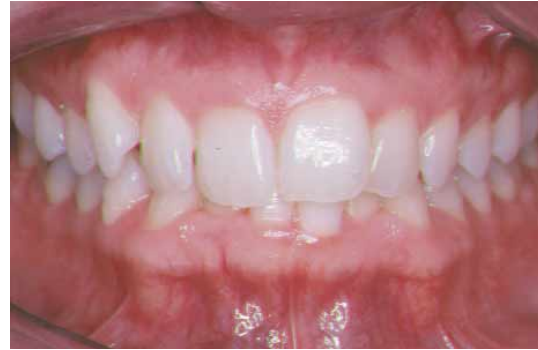

Fig 13. Dental relationships were distinguished by crowded maxillary and mandibular incisors and 100% deep bite.

The cephalometric superimpositions reflect the changes accomplished with the total orthodontic and orthopedic treatment. Superimposition on the palatal plane (Fig 10) demonstrates the uprighting of the maxillary anterior teeth with the rotational effect that resulted in retraction and lengthening of the maxillary incisors relative to the upper lip. This movement improved the smile by increasing tooth display. The mandibular superimposition demonstrates the uprighting and retraction of mandibular incisors, which contributed to closure of the open bite. The overall superimposition (Fig 11) documents that the rotation of the palatal plane was favorably clockwise, and the amount of mandibular growth was significant, resulting in a remarkable improvement in the skeletal relationships.

This case illustrates nicely the principle of the face as determinant of treatment choice because the growth modification and orthodontic mechanics were all chosen, not just to correct the malocclusion, but to improve facial esthetics as well.

Case 2

This 35-year-old woman came for treatment with a chief complaint of dental crowding. Her frontal facial proportions at rest were normal, and an evaluation of her smile line revealed an ideal incisor curvature to the lower lip line (Fig 12). Her dental relationships (Fig 13) were distinguished by crowded maxillary and mandibular incisors and a 100% deep bite.

Treatment choices in regard to both orthodontic problems have esthetic ramifications that must be considered. Options for treatment of crowding include expansion of the arches or extraction of first or second premolars. The criteria would include the amount of crowding, the vertical skeletal pattern, periodontal condition and attachment, and profile considerations. In

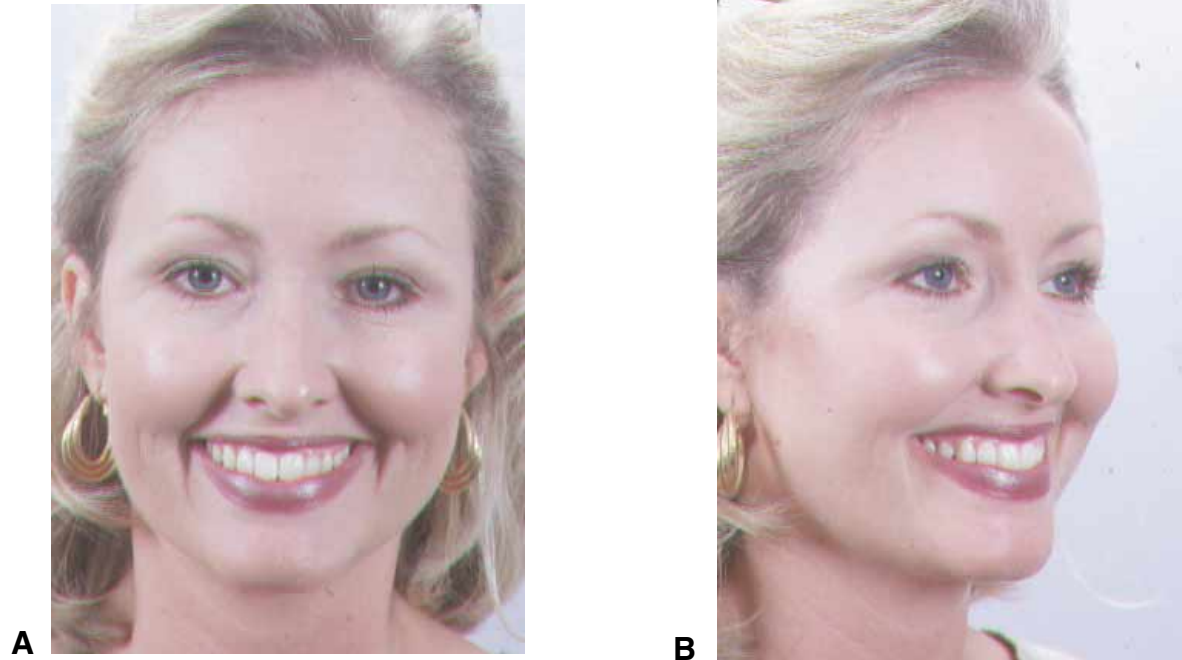

Fig 14. **A**, Frontal view shows beautiful smile with excellent incisor display; **B**, 45° view shows consonance of maxillary anterior dental curvature with curvature of lower lip.

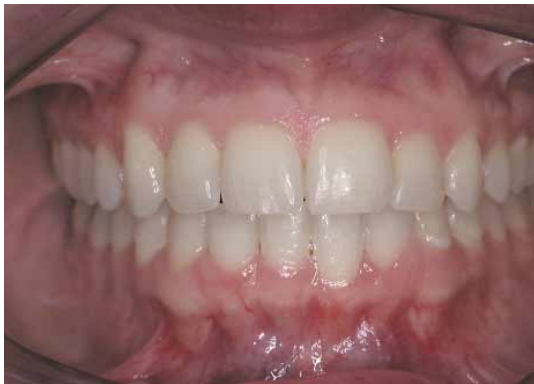

Fig 15. Final dental result was good functionally and esthetically, with alignment and bite opening achieved.

this case, the amount of gingival attachment on the mandibular incisors was adequate and the amount of crowding was moderate. Nonextraction treatment would produce more lip fullness to counteract the normal thinning of the lips that occurs with aging.¹⁶ It was decided to treat the crowding problem without extraction by flaring the mandibular incisors forward. This movement would moderately increase lip protrusion.

Several options were considered for correction of the deep overbite. Alignment and leveling with normal bracket positions and conventional accentuated or

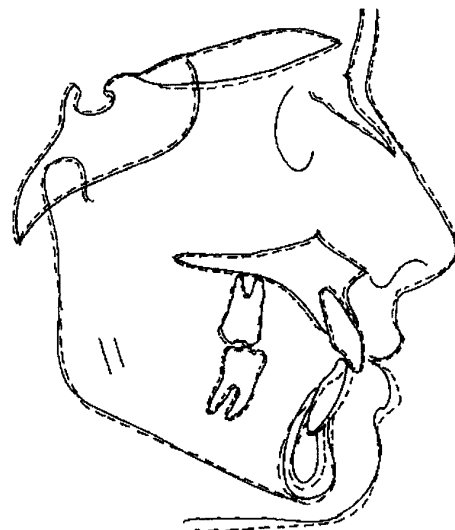


Fig 16. Overall cephalometric superimposition reflects flaring of mandibular incisors resulting in bite opening (advancement of mandibular incisor crown with its rotation point at root apex; this resulted in a more inferior position of incisal tip) and increased lower lip fullness.

reverse curve archwires was one option. This treatment might result in some undesirable leveling of the maxillary arch. Because the smile arc would be affected by this maxillary leveling, it was important to maintain the

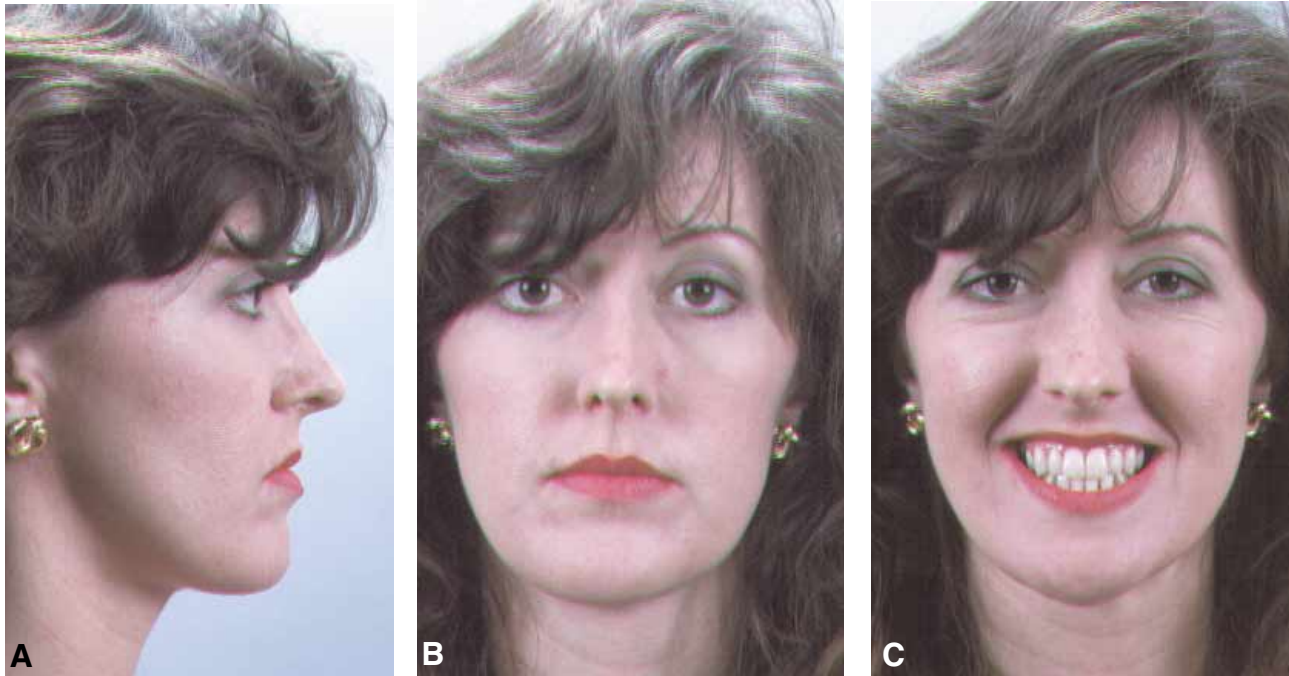

Fig 17. **A**, Profile exhibited strong lower face, with lower lip more prominent than upper lip; **B**, lower facial height was long with disproportionately long chin; upper lip comprised only 25% of lower facial vertical third, and lower lip and chin comprised 75%; **C**, on smile, there was slightly more gingival display in posterior aspect of smile than in anterior display. Posterior maxilla was tilted with moderate posterior cant that contributed to flat smile arc relative to curvature of lower lip.

maxillary incisor position rather than to intrude the maxillary incisors during any phase of leveling.

Extrusion of the posterior teeth would also help to correct the deep overbite. This option offered the advantage of not changing the smile arc while having a tendency to increase the lower facial height. However, there is evidence that posterior dental extrusion is difficult in adult patients.¹⁷

Another option was intrusion of the mandibular incisors. This would permit us to leave the maxillary incisors vertically where they were, so that the smile arc would be protected. Inferior positioning of the mandibular incisor crowns can occur through 2 mechanisms: intrusion arch mechanics (like a utility arch or auxiliary intrusion arch) or inferior positioning of the crowns with anterior tipping of the teeth through leveling with reverse curve lower archwires. Reverse curve archwires place an intrusive force on the bracket anterior to the center of resistance, resulting in labial flare and a decrease in crown height.

Bite opening was to be achieved with bracket placement on the maxillary incisors to maintain the present maxillary incisor vertical position, and placement of the mandibular incisor brackets nearer to the incisal

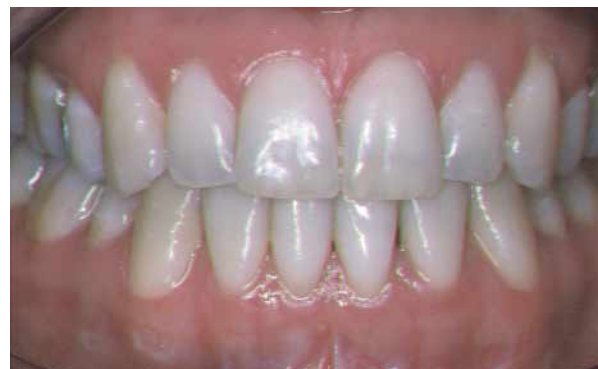

Fig 18. Occlusal relationships were quite good; however, some slight dental compensation (uprightness of mandibular incisors) was still present.

edge than to the center of the tooth. Bracket placement is very important to protect the maxillary smile arc and to avoid the complications noted in Figure 4, *A* and *B*. Reverse curve lower archwires, with flat upper archwires, were also used to achieve bite opening.

Total treatment time was 14 months. The frontal view shows a beautiful smile with excellent incisor display (Fig 14, *A*). The 45° view shows the consonance

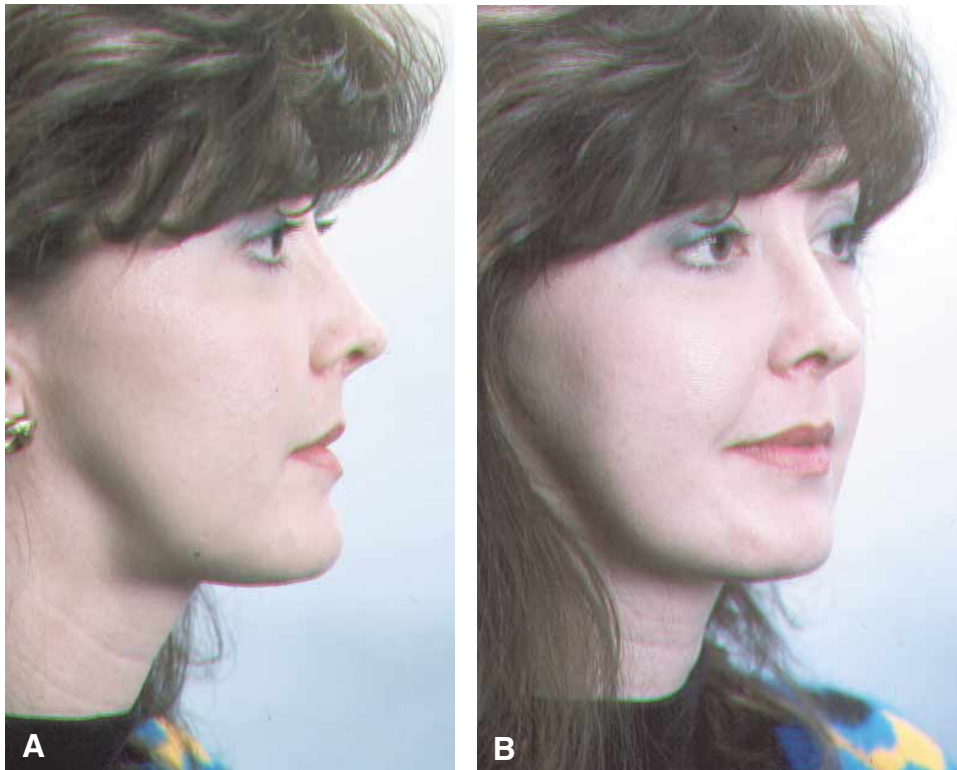


Fig 19. A, After maxillomandibular surgery and clockwise occlusal plane rotation with rhinoplasty and vertical genioplasty, profile was improved in facial height, nasal form, and lip balance; **B,** 45° view reflects contribution of advancement of maxilla and change in upper lip projection relative to lower lip, along with refinement of midface by means of rhinoplasty.

of the maxillary anterior dental curvature with the curvature of the lower lip (Fig 14, *B*). The final dental result was good, both functionally and esthetically, with alignment and bite opening achieved (Fig 15). The overall cephalometric superimposition shows that the maxillary incisors and molars remained virtually unchanged vertically, whereas the mandibular incisors were tipped facially (Fig 16). This produced more lower lip fullness and resulted in a more inferior position of the incisal tip. This was not true intrusion but it did have the effect of opening the bite.

Obviously, this patient could have been treated in a number of ways and maintained her attractive appearance. But attention to maintaining her existing incisor-to-lip relationship, so that the orthodontic mechanics did not alter the smile arc, enhanced the esthetic outcome.

Case 3

This 28-year-old patient had a history that included orthodontic treatment as an adolescent with 4 premolar extractions, followed by an unfortunate period of Class III growth. She underwent orthodontic retreatment with

mandibular reduction at age 24. She was seeking further treatment because she felt she had not attained the esthetic benefit of treatment that she desired. A systematic evaluation included the profile, frontal at rest, frontal on smile, and dental relationships.

Profile. The profile problem list was characterized by a nasal tip that was slightly over-projected and located more inferiorly than was desirable (Fig 17, *A*). The nasolabial angle was slightly acute because of low nasal tip placement. The upper lip was not as procumbent as the lower lip, and the mandible was slightly ahead of the maxilla.

Frontal at rest. The lower facial height was long with a disproportionately long chin (Fig 17, *B*). The upper lip comprised only 25% of the lower facial vertical third, while the lower lip and chin comprised 75% of the lower facial height (a 1:2 ratio is more esthetic). Nasal width was slightly narrower than the intercanthal width, and the vermilion show of the upper lip was slightly less than that of the lower lip.

Frontal on smile. On smile, the transverse smile relationships were quite good, and the amount of gin-



Fig 20. **A**, Final frontal picture characterized by slightly wider nose; vertical facial proportionality improved significantly by shortening of chin height; **B**, smile relationship was changed with elimination of posterior gingival display. Consonance of occlusal plane and lip line improved dramatically by means of surgically tilting palatal plane.

gival display in the upper central area was excellent (Fig 17, C). However, there was slightly more gingival display in the posterior aspect of the smile than the anterior display. The posterior maxilla was tilted with a moderate posterior cant that contributed to a flat smile arc relative to the curvature of the lower lip.

Dental relationships. The occlusal relationships were excellent. However, some dental compensation (uprightness of the mandibular incisors) was still present (Fig 18).

The observations outlined above can be broken down into treatment options, starting from superior to inferior:

1. Nasal overprojection. Consider rhinoplasty for reduction of tip projection, as well as rotation of the tip more superiorly to improve the nasolabial angle.
2. Retrusive upper lip relative to lower lip. Although movement of the lower lip back is an option, this would tend to flatten the profile, and 2 mandibular premolars had already been removed. Maxillary advancement might be considered, but was contraindicated because of the existing Class I occlusion.
3. Maxillary lip augmentation with rhinoplasty. This is an option but is unpredictable.

The frontal facial relationships and the treatment of the smile line virtually dictated the rest of the orthodontic and orthognathic treatment plan. Because of the posterior gingival display and the flatness of the smile arc, posterior maxillary impaction was recommended to reduce posterior gingival display and tip the occlusal plane clockwise. This movement would improve the posterior smile line and, at the same time, tip the maxilla so that the incisal alignment is more consonant with the lower lip, resulting in a better smile arc.

The profile would be favorably affected by the clockwise occlusal plane rotation. Because of the tip to the maxilla, the anterior nasal spine would travel forward when the anterior tip of the maxilla is performed surgically, and some maxillary advancement could also be performed. Then the mandible would necessarily be repositioned surgically to rotate it in a clockwise fashion to compensate for the changed palatal plane. This, in essence, would rotate the mandible back, while the maxilla travels forward.^{18,19} The posterior maxillary impaction would also upright the flared maxillary incisors relative to the upper face. Vertical chin reduction was also recommended as part of the treatment plan. Recall that the vertical proportions of the lower face were less than ideal, with the upper lip represent-

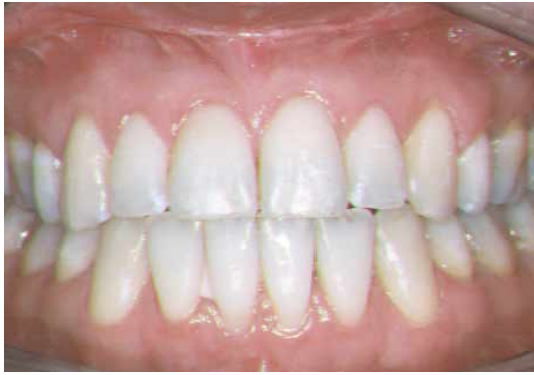

Fig 21. Final occlusal photographs reflect good final relationships.

ing 25% of the facial height and the lower lip and chin 75%, as compared with the one third-to-two thirds ideal. Therefore, a wedge genioplasty was planned to shorten the lower facial height.

The surgical plan summary was as follows:

1. Maxillomandibular surgery to rotate the occlusal plane and lower face in a clockwise fashion was chosen. The point of rotation was planned to be at the incisal edge, with the posterior maxilla going up approximately 3 mm (the amount of gingival display measured on smile) and no anterior impaction because the incisor-to-lip relationships were ideal. Rotation around the incisal edge to bring the upper part of the maxilla forward was designed to improve lip projection and widen the slightly narrow nose. The mandibular procedure would rotate the mandible in a clockwise fashion and thus reduce mandibular projection and balance the lower lip with the upper lip.
2. Adjunctive and simultaneous rhinoplasty would be performed to elevate the nasal tip and reduce projection. No effort was made to control nasal width because a wider nose was desired.
3. Vertical genioplasty with wedge reduction to reduce the chin height and normalize facial heights was planned.

Figure 19, A, represents the finished profile. The elevation of the nasal tip and the elegance provided by the rhinoplasty dramatically improved the appearance of the midface. Also note the improved relationship of the upper lip to the lower lip, and the increased vermilion show in the upper lip. The reduction in chin height improved the vertical facial proportionality, but also deepened the labiomental sulcus, which was flatter in the preoperative picture. It is important to look at the patient at a 45° angle (Fig 19, B) and note the contri-

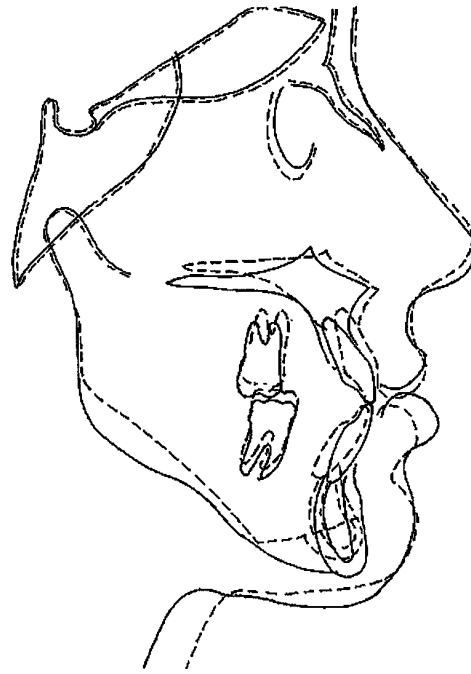


Fig 22. Cephalometric superimposition reflects clockwise rotation of occlusal plane by means of posterior maxillary impaction and saggital split osteotomy.

bution of the advancement of the maxilla and the change in upper lip projection relative to the lower lip and, again, the refinement of the midface with rhinoplasty.

The final frontal picture (Fig 20, A) is characterized by a slightly wider nose, and the vertical facial proportionality improved significantly by the shortening of the chin height. Finally, Figure 20, B, represents the change in the smile relationships, with the posterior gingival display eliminated. The consonance of the occlusal plane and the lip line was improved dramatically.

The limiting constraint in this case was the contour of the lower lip in relation to the smile arc. For this patient, surgery was the only option that could change these relationships. The final occlusal relationship is shown in Figure 21.

The cephalometric superimposition (Fig 22) reflects the clockwise rotation of the occlusal plane by means of posterior maxillary impaction and saggital split osteotomy. Note that the maxillary incisor position was maintained vertically and horizontally while the palatal plane rotated around the incisal edge, which resulted in advancement of the superior portion of the maxilla and more upper lip and midfacial fullness. The clockwise rotation of the mandible resulted in less

emphasis in mandibular projection as well, all of which (with vertical chin reduction) resulted in a superior facial result as well as superior smile esthetics.

CONCLUSIONS

The concept of the smile arc is not a new one, as the literature review has shown. Clearly, its impact on the final facial and smile appearance can be quite dramatic. This demands that we rethink some of our orthodontic mechanics and concepts of treatment to consistently build this factor into our diagnostic, treatment planning, and treatment regimens.

I would like to acknowledge the contribution of Dr Jim Ackerman of Bryn Mawr, Pa, in the development of this article.

REFERENCES

1. Lavater JC. Essays on physiognomy, Vol 1-3. London: J&J Robinson; 1789.
2. Peck S, Peck L. Selected aspects of the art and science of facial esthetics. *Semin Orthod* 1995;1:105-26.
3. Ackerman J, Ackerman MB, Brensinger CM, Landis JR. A morphometric analysis of the posed smile. *Clin Orthod Res* 1998;1:2-11.
4. Hulsey CM. An esthetic evaluation of tooth-lip relationships present in smile. *Am J Orthod* 1970;57:132-44.
5. Rigsbee OH, Sperry TP, BeGole EA. The influence of facial animation in smile characteristics. *Int J Adult Orthodon Orthognath Surg* 1988;3:233-9.
6. Sarver DM. Esthetic orthodontics and orthognathic surgery. St Louis: Mosby; 1997.
7. Sarver DM, Proffit WR, Dickson S. The dynamics of the maxillary incisor and the upper lip—a cross sectional study of resting and smile hard and soft tissue characteristics. *World J Orthod*. In press 2001.
8. Vig RG, Brundel GC. Kinetics of anterior tooth display. *J Prosthet Dent* 1978;39:502-4.
9. Frush JO, Fisher RD. The dysesthetic interpretation of the denotogenic concept. *J Prosthet Dent* 1958;8:558.
10. Ackerman, M. The effect of maxillary position on anterior tooth display [thesis]. Rochester (NY): University of Rochester; 2000.
11. Sarver DM. The face as determinant of treatment choice. In: *Frontiers of dental and facial esthetics*. Craniofacial Growth Series, Center for Human Growth and Development. Ann Arbor: University of Michigan; 2001. Vol 38, p. 19-54.
12. Goldstein RE. Change your smile. 3rd ed. Carol Stream (Ill): Quintessence Publishing; 1997.
13. Zachrisson BU. Esthetic factors involved in anterior tooth display and the smile; vertical dimension. *J Clin Orthod* 1998;32:432-45.
14. Sarver DM, Ackerman JP, Proffit WR. Diagnosis and treatment planning in orthodontics—the modern soft tissue paradigm. In: Graber T, Vanarsdall R, editors. *Orthodontic practice and principles*. 3rd ed. St. Louis: Mosby; 2000. p. 3-115.
15. Hayes RJ, Sarver DM, Jacobson AJ. Quantification of cervico-mental angle changes with mandibular advancement. *Am J Orthod Dentofacial Orthop* 1994;105:383-91.
16. Mamandras AH. Linear changes of the maxillary and mandibular lips. *Am J Orthod Dentofacial Orthop* 1988;94:405-10.
17. Pearson LE. The management of vertical dimension problems in growing patients. *Craniofacial Growth Series, Center for Human Growth and Development*. Ann Arbor: University of Michigan; 2000. Vol 36.
18. Sarver DM. Diagnosis and treatment planning of hypodivergent skeletal pattern with clockwise occlusal plane rotation. *Int J Adult Orthodon Orthognath Surg* 1993;8:113-21.
19. Reyneke JP, Evans WG. Surgical manipulation of the occlusal plane. *Int J Adult Orthodon Orthognath Surg* 1990;5:99-110.